SPECIAL

visions

MAGAZINE FOR HEALTH PROFESSIONALS
European Edition // Neurology Special // No 1 // August 2021

Canon

Cover Image:
The image on the cover is one of the visuals of our Made For Life campaign and is representing Neurology.
To view our Made For Life campaign video, you can visit our website:
https://eu.medical.canon/about/madeforlife

This Neurology Special edition of VISIONS magazine is a publication of Canon Medical Europe and is offered free of charge to health professionals. To download the full digital edition of this Special, please visit: https://eu.medical.canon/visions-magazine. In the VISIONS Blog section on our website, you can download VISIONS articles separately. Previous VISIONS editions can be downloaded from: https://eu.medical.canon/visions-magazine/archive.

VISIONS magazine is covering Canon Medical's European region and as such reflects products, technologies and services for this particular area. The mentioned products may not be available in other geographic regions. Please consult your Canon Medical representative sales office in case of any questions.

News, articles and the full edition of VISIONS magazine are announced firstly, as pre-publication, via the dedicated VISIONS LinkedIn Group: https://www.linkedin.com/groups/3698045. In this group you can actively participate in discussions about the content and future direction of the magazine.

Publisher
Canon Medical Systems Europe B.V.
Zilverstraat 1, 2718 RP Zoetermeer
The Netherlands
+31 79 368 92 22
W: https://eu.medical.canon/
E: visions.eu@eu.medical.canon

Editor-in-chief
Jacqueline de Graaf
(European Senior Project Manager Marketing)
jacqueline.degraaf@eu.medical.canon

Design & Layout
Boerma Reclame
boermareclame.com

Printmanagement
Printweb Media B.V.
printweb.nl

Photography
Cojan van Toor
www.cojanvantoor.nl

Text contributions and editing
Mélisande Rouger - Independent Journalist
Sara Sharp - The Creative Practice

Follow us:

 ISSN 1617-2876

// INTRODUCTION

Dear Readers,

We are delighted to present you with this Special Neurology Edition of VISIONS Magazine, which shows how clinical experts utilize Canon's state-of-the-art technology to deliver the very best in Neurology solutions.

Neurology has never been more important, or more exciting. As our populations age, the global burden of neurological diseases is growing, but research and innovation in this field are progressing rapidly to provide new solutions. Canon Medical strives to be the 'Voice of Neurology'.

This VISIONS Special edition is filled with fascinating articles and information that illustrate how some of the world's leading experts leverage towards a common goal.

We introduce Canon Medical's forthcoming Neurology Days – a five-day, online Neurology conference, which will deliver forward-looking, multi-topic education for neurologists, radiologists, interventional radiologists and anyone else with an interest in Neurology. You can join the interactive webinars, led by subject matter experts from across the globe, and find out more about state-of-the-art imaging and clinical management through illustrative clinical examples. You can also discover how Canon Medical's key technologies work in clinical practice and research.

With a collection of selected Neurology articles from VISIONS, you can follow the evolution of our innovations. Learn how our technology answers the clinical questions of today, and discover how we can use it to formulate the questions of tomorrow.

Our experts and collaborations are at the heart of our innovation and progress. Without them, we would not be able to become the 'Voice of Neurology'. We extend our thanks to the panelists and contributors for helping us to make this Special edition available to you.

Are you ready for the future of Neurology? We look forward to seeing you online at our Neurology Day webinars, at which we will discuss one of the most exciting and fastest growing fields of healthcare.

Kind Regards,

Canon Medical Systems Europe.

// CONTENTS

Online Neurology Days
Starting August 24

Never before has the field of neurology been more important, or more exciting. According to Global Burden of Disease study in Lancet[1], neurological disorders are the leading cause of disability and second cause of death globally, with the burden set to increase with an aging population. Fortunately, scientific breakthroughs continue to emerge driving change in clinical practice.

Canon Medical, together with our partners, strives to be the voice of neurology by bringing together experts to share discoveries and insights from research and clinical practice. The Canon Online Neurology Days consists of daily interactive webinars, led by subject matter experts from across the globe. This week will provide a platform for professional education as we discuss state-of-the-art imaging and clinical management using illustrative clinical examples.

Over the course of five days, this virtual neurology conference will deliver forward-looking, multi-topic education for neurologists, radiologists, interventionalist and any other with an interest in neurology.

We will begin by following an acute stroke patient pathway over three days from early detection, through acute diagnostics and into the Angio suite. Then we look through the eyes of a patient to learn about diagnostic advancements in multiple sclerosis. The final day diverges to the peripheral nervous system as we explore innovative solutions for visualization and treatment of peripheral nerve injury.

Click here to view the Program of the 'Online Neurology Days

All live webinars start at 19:00 CET, 60 minutes.

Stroke

Globally, stroke is a leading cause of mortality and disability with the World Stroke Organization reporting an annual mortality rate of five and a half million people[2]. Additionally, up to 50% of survivors have chronic disability posing a major public health problem and substantial economic burden.

The last five years has been transformative for stroke treatment and clinical practice due to the landmark thrombectomy trials.

However, with an aging population and an increasing burden in low-income and middle-income countries, the attention also must turn to effective preventative measures to supplement these recent advances of stroke treatment.

Over three days we will uncover techniques offering opportunities to detect those at risk as well as discuss the latest in diagnostic and treatment pathways based on the ever-shifting guidelines of recent years.

Day 1 STROKE Symptoms

Aug 24, 2021 | 19:00 CET

SPEAKER
Prof. Neil D Pugh, Cardiff University, Spire Hospital Cardiff

'Ultrasound Imaging of the Carotid Artery in Stroke Assessment'



SPEAKER
Dr. Mahtab Zamani (Oslo University Hospital Rikshospitalet, Norway)

'Detection of Neovascularization with Advanced Ultrasound Method (SMI) without Using Contrast Material'

Identifying who is at risk of stroke remains a high priority according to the US preventative Services Task Force[3]. Learn how Ultrasound and Superb Microvascular Imaging (SMI) imaging may play a role in risk stratification by imaging Carotid plaque instability.

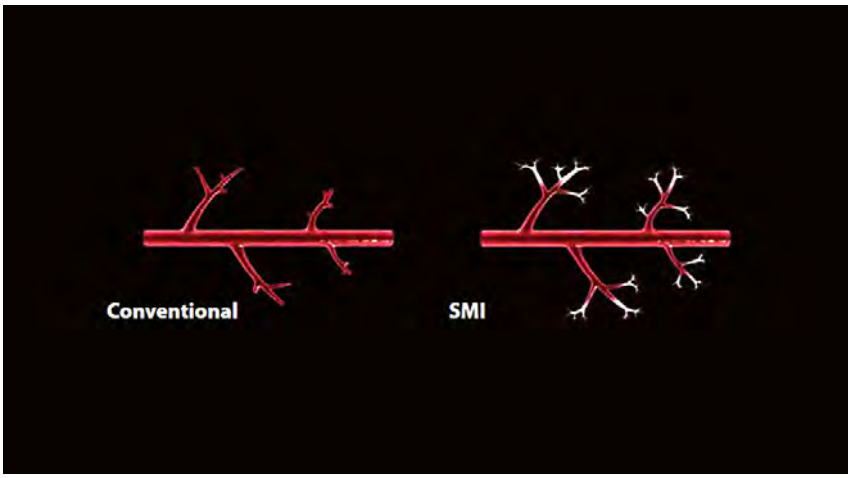

SMI: Traditional color Doppler imaging (left) removes clutter from the images by suppressing low-velocity components, resulting in a loss of flow in tiny vessels.SMI (right) separates flow from overlaying tissue motion effectively, while preserving even the subtlest low-flow components with unmatched detail and definition.

Day 2 STROKE Diagnostics

Aug 25, 2021 | 19:00 CET

SPEAKER AND MODERATOR
Dr. Grant Mair (The University of Edinburgh, UK)

'Imaging for Acute Stroke, the Basics of Acquisition and Interpretation'

SPEAKER
Dr. Anton Meijer (Radboudumc, Nijmegen, the Netherlands)

'State-of-the-Art Brain CT Perfusion in Acute Ischemic Stroke'

SPEAKER
Dr. Josep Puig (University Hospital Dr. Josep Trueta (IDI) and Center of Comparative Medicine and Bioimaging of Catalonia, Spain)

'Diffusion Tensor Imaging as a Biomarker for Stroke Patients'

Imaging has been the backbone of the acute stroke treatment revolution that has brought thrombectomy to an ever-increasing number of eligible patients. Join our panel of experts to discuss how guideline updates and revised recommendations translate into clinical practice. Learn the diagnostic strategies that can be applied using both baseline and state-of-the-art imaging.

Whole Brain Perfusion with Area Detector CT

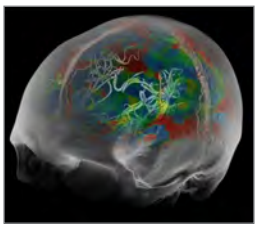

Bayesian Brain Perfusion & Automation Platform

Galan 3T

Day 3 STROKE Treatment

Aug 26, 2021 | 19:00 CET

MODERATOR
Dr. Andrés González Mandly (University Hospital Marques de Valdecilla of Santander, Spain)

SPEAKER
Dr. Nevia Caputo (Azienda Sanitaria de locale Teramo, Italy)

'Endovascular Therapy in Neurological and Neurosurgical Emergencies'

SPEAKER
Prof. Adnan Siddiqui (University of Buffalo, NY, USA)

'Higher Definition, Easier Procedure, Better Outcomes'

Whilst thrombectomy has transformed acute stroke care, the key factor in treatment remains speed. How do you make the best decisions and perform intricate procedures under such time pressure? Our speakers will bring to life their clinical practice by sharing real life case studies whilst highlighting the benefits of using state-of-the-art high-definition imaging systems.

Alphenix Biplane solutions



Hi-Def Detector



DoseRite

Day 4 Multiple Sclerosis

Sep 1, 2021 | 19:00 CET

SPEAKER
Dr. Benoît Doche de Laquintane, Medical Imaging Group IMAGIR, Bordeaux, France

'Practical Imaging of Neuro-Inflammatory Diseases in Daily Clinical Routine'

SPEAKER
Prof. Bart van Wijmeersch, Hasselt University, Belgium

'The Current Use of OCT in MS Care'

SPEAKER
Prof. Thomas Tourdias, Bordeaux University Hospital, France

'Advanced Imaging in MS'

Worldwide 2.8 million people are living with multiple sclerosis[4] which is an unpredictable and often disabling disease with no cure. A growing arsenal of disease-modifying therapies offers opportunities to reduce disability and extend survival. However, for maximum benefit biomarkers are needed. A complete picture of Multiple Sclerosis requires combination of markers of inflammation and neurodegeneration. We will paint that picture by sharing diagnostic strategies for imaging neuroinflammatory disease in routine clinical practice as well as offering a window into the brain using optical coherence tomography (OCT).

Galan 3T XGO

Xephilio OCT-A1

Galan 3T ZGO

Day 5 Peripheral Nerve Disease

Sep 2, 2021 | 19:00 CET

SPEAKER
Dr. Nens van Alfen (Radboudumc, Nijmegen, the Netherlands)

SPEAKER
Dr. Alexndra Borchert (Pauwelsklinik Aachen, Germany)

'Neuromuscular Ultrasound - a Game Changer for your PNS Diagnostics'

More than 100 types of peripheral neuropathy have been identified[5], each with its own symptoms and prognosis which can range from mild to severely disabling. The therapeutic management of peripheral nerve disorders requires detailed information about localization and extent of an injury. Can you see what we see? Join our experts to discover why imaging has an important role in peripheral nerve system diagnostics and learn how neuromuscular ultrasound can transform your clinical practice.

Ultra High Frequency probes above 20MHz

References:

1. Click here to visit thelancet.com
2. Click here to visit world-stroke.org
3. Click here to visit jamanetwork.com
4. Click here to visit msif.org
5. Click here to visit ninds.nih.gov

Alphenix Biplane Hi-Def: A Point Where Cutting-Edge Technologies and Fine Art Meet

Dr. Ljubisa Borota, Uppsala University, Sweden

Canon Medical and the Department of Radiology, Uppsala University Hospital, Sweden, will celebrate this November the ten-year anniversary collaborative partnership in our neurointervention laboratory. The relationship between Canon Medical and our section has never been an ordinary supplier-customer relationship. These ten years have been marked by mutual efforts in the development of the biplane system and on work that has focused on an analysis of the unique functionalities of this system. The conclusions of our strategic discussions are implemented by Canon's R & D teams. All challenges have been overcome thanks to energy, motivation and, first of all, the deep mutual respect which was established during the many years of our collaboration. The Alphenix Biplane system that was launched was partly the result of these mutual efforts.

Our work was focused on an analysis of the unique functionalities of the Alphenix system that make it different and superior to other biplane systems. The goal of our analyses was to become familiar with these novel functionalities in order to use them in our daily work in an optimal way. An additional objective was to publish our observations and the results of analyses in scientific journals. In this way the results of our work received scientific confirmation and became more accessible to practitioners and scientists in the field of neurointervention on a global level.

The Alphenix Biplane with Hi-Def at Uppsala University, Sweden.

Dose saving functionalities

Information regarding the dose delivered to the patient is of key importance to the operator. In all biplane systems except for the Alphenix Biplane, this information is shown in numerical form somewhere on the monitor together with less important information. Based on the research of Bednarek and colleagues[1], Canon has developed a system that shows the area of the body that is exposed to the irradiation. The spectrum of colors in this area changes from dark blue to dark red, indicating delivered skin dose. This 3D model is displayed in the corner of the screen, and, since it is only a 3D color indicator, it keeps the operator continuously updated about the dose without being intrusive.

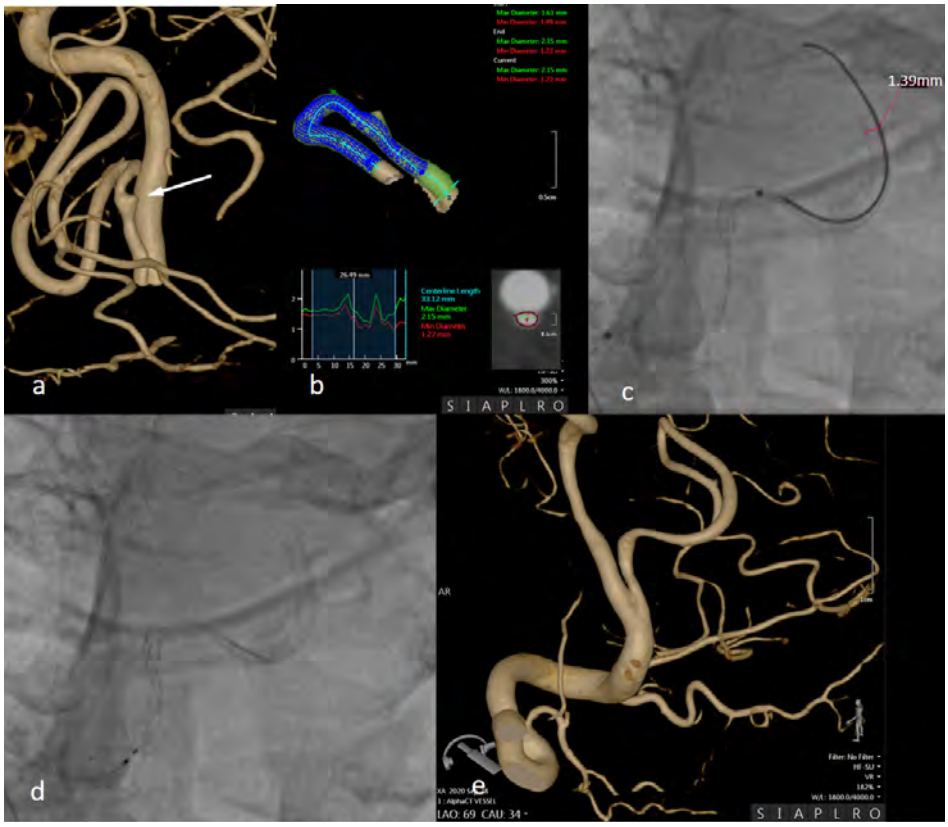

Figure 1:

a. 3D reconstruction: dissecting aneurysm (arrow) of posterior inferior cerebellar artery (PICA).

b. Virtual stenting indicates that the largest diameter of artery is 2.15 mm and the smallest 1.22 mm.

c. High Def: a flow diverting stent is deployed.

d. High Def: a second, braided stent is deployed in telescopic fashion in proximal segment of PICA and vertebral artery due to proximal extension of the dissection.

e. 3D reconstruction: one week follow-up shows completely reconstructed artery.

Spot Fluoroscopy is a unique technology that enables acentric, asymmetric collimation anywhere within the field of view. The shape (square or rectangle), size or place of the region of interest defined by such collimation can be changed at any time during the intervention, and as many times as the operator needs to do it. Using this functionality, it is possible to adapt the field of view to the anatomy of a vascular target, enabling optimal visualization of the target with the lowest possible dose. We have shown that the dose delivered to a patient by using Spot Fluoroscopy is significantly lower than the dose delivered using conventional collimation[2].

A similar, dose-sparing functionality referred to as Spot Region of Interest (Spot ROI), which is integrated in the Alphenix Biplane system, offers a square-shaped collimation of the region of interest that is freely movable within the field of view[3]. Unlike other collimation systems, the field of view outside the region of interest is still visible, which is particularly important in visualization of larger anatomical regions.

Another functionality that distinguishes this machine from any other biplane system is the flexible lateral isocenter. This functionality "enables mobility of the lateral arm in the vertical direction and in this way contributes to the adjustability of the lateral arm and thus to better visualization of vascular structures regardless of their position, size or shape. Thanks to this novel functionality, it is also possible to obtain the desired projections with the minimal possible distance between the detector plate and X-ray tube."[4]. A shorter source-detector distance also leads to a dose reduction according to the inverse square law. We have shown that the dose delivered to the target by using a flexible lateral isocenter is significantly lower than the dose delivered to the same target by using a fixed lateral isocenter[4].

Beyond the imaginable...

Finally, the last jewel in the crown of Alphenix Biplane system is the High Definition (Hi-Def), one more functionality that distinguishes this machine from other biplane machines. The system is equipped with a novel hybrid flat panel detector on each plane that consists of a standard 30x30 detector and a built in 8x8cm High definition detector with a pixel size of 76µm providing 6,5LP/mm resolution. This unique high-resolution mode enables superior visualization of both the smallest anatomical structures and the smallest neurovascular devices. Clinical importance of this functionality has already been confirmed[5]. Manufacturing technology of neurovascular devices has developed tremendously during recent years. The range of sizes of the smallest aneurysms now treatable by endovascular means varies between 1 mm and 3 mm. The diameter of the loop of the smallest coil measures 1 mm and the total length of this coil measures 10 mm. High definition enables visualization of even the secondary structure of these coils.

Figure 2:
a. AP projection, spot image without magnification shows coils in an aneurysm (arrowhead), a flow diverting 2.5 x 25 Silk stent in middle cerebral artery (arrow) and a 3.75x25 Silk Vista Baby flow diverting stent in internal carotid artery (double arrow).
b. Digital subtraction angiography, same projection without magnification.

Newly developed flow-diverting stents can be deployed even in arteries with a diameter between 1.5 mm and 2 mm (Figure 1). The new generation of these stents is fully visible thanks to new technologies that have enabled the manufacturing of the micro wires these stents are made of. Figures 2 and 3 illustrate in the best possible way the tremendous progress that has taken place in the development of endovascular devices. A wide-necked middle cerebral artery aneurysm was treated with coils and a flow-diverting stent in 2017. An ophthalmic artery aneurysm was treated with only a flow-diverting stent in 2021. Both stents were designed and produced by the same manufacturer. The image shown in the Figure 3 was taken using the High Definition function integrated into the Alphenix Biplane system. The first, strong impression is that the stent used in 2017 was not only partly visible but also primitive in comparison with the stent used in 2021. Even though the image is two-dimensional, it is not difficult to get a three-dimensional perception of a complex, tapered cylindrical structure made up of numerous densely braided micro wires and bent in several planes. The development of Canon's Alphenix Biplane system very successfully follows the development of neurovascular devices. Thanks to this development, the treatment of even the smallest vascular targets with the finest neurovascular devices has never been as safe and reliable as it is now.

Dr. Ljubisa Borota, Uppsala University, Sweden.

Instead of a conclusion…

The Alphenix Biplane is a unique system from several points of view. Elegantly designed arms combined with a flexible lateral isocenter offer almost unlimited adaptability to the shape and size of vascular targets. It is not an exaggeration to claim that impossible working projections do not exist with this machine. Multiple dose-saving functionalities contribute to the reduction of the dose to the patient and to the staff to the lowest possible values.

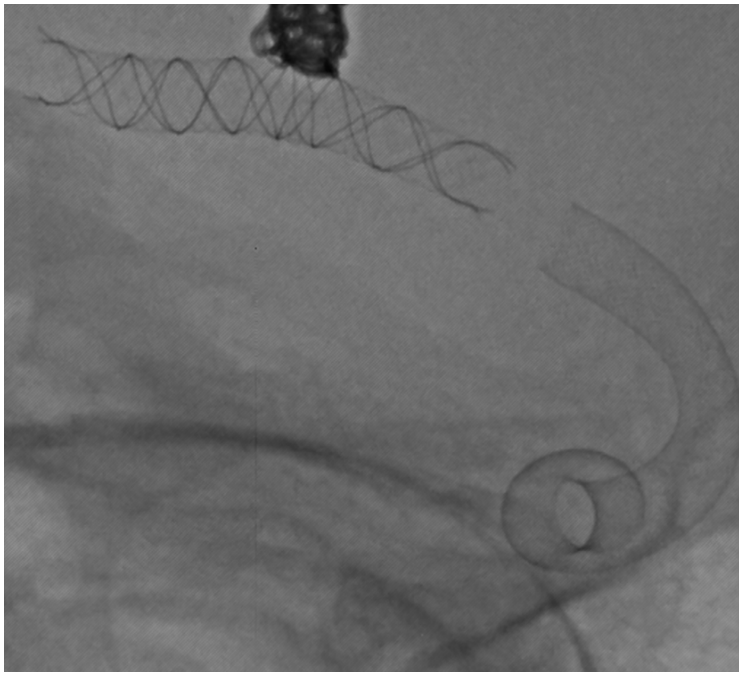

Figure 3:
The same case as on the Figure 2. Stents and coils are visualised by High Definition.

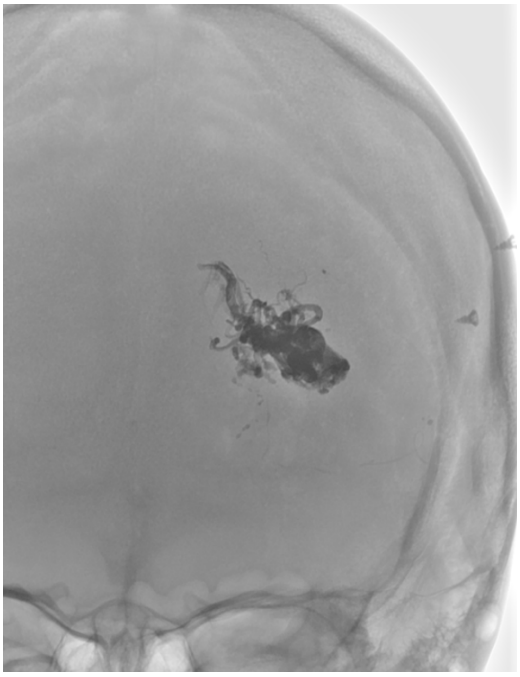

Figure 4:
Onyx cast in cerebral AVM ... or in art analogy: the take-off of a black swan.

Neurointervention is somewhere between fine art and medicine... Sometimes, closer to fine art... The aim of our interventions is to re-open or reconstruct pathways for the blood supplying the brain or to fill bizarre cavities, aneurysm, fistulas or AVMs, with some of the numerous embolic materials available. A neurointerventionalist is like a sculptor who creates bizarre casts in the brain vasculature that remind one of modern abstract sculptures (Figure 4).

The High Definition function offers not only excellent visualization of the smallest anatomical structures and the smallest devices and their ultrastructure, but also offers the operator a unique visual, artistic experience. This machine is really the point where cutting-edge technologies and fine art meet. //

Visit our website or scan the QR code:
https://eu.medical.canon/products/angiography/alphenix/neurology

References

[1] *Bednarek, Daniel, Barbarits, Jeffery, Rana, Vijay, Nagaraja, Srikanta, Josan, Madhur: Verification of the performance accuracy of a real-time skin-dose tracking system for interventional fluoroscopic procedures. Proc. SPIE 7961, Medical Imaging 2011: Physics of Medical Imaging, 796127 (16 March 2011); doi: 10.1117/12.877677*

[2] *Borota L, Jangland L, Åslund P-E, Ronne-Engström E, Nyberg C, Mahmoud E, Sakaguchi T and Patz A: Spot fluoroscopy: a novel innovative approach to reduce radiation dose in neurointerventional procedures. Acta Radiologica, 2017 May;58(5):600-608. doi: 10.1177/0284185116658682.*

[3] *Borota L, Patz A: Spot region of interest imaging: a novel functionality aimed at x-ray dose reduction in neurointerventional procedures. Radiat Prot Dosimetry, 2020 Jun 24;188(3):322-331. doi: 10.1093/rpd/ncz290.*

[4] *Borota L, Patz A: Flexible lateral isocenter: A novel mechanical functionality contributing to dose reduction in neurointerventional procedures. Interv Neuroradiol 2017 Dec;23(6):669-675. doi: 10.1177/1591019917728260.*

[5] *Nagesh SVS, Vakharia K, Waqas M, Munich S, Bednarek B, Davies JM , Kenneth V Snyder KV, Mokin M, Rudin S, Levy E, Siddiqui AH: Single-center experience of using high definition (Hi- Def) imaging during neurointervention treatment of intracranial aneurysms using flow diverters. J NeuroIntervent Surg 2020; 12:897–901. doi: 10.1136/neurintsurg-2019-015551*

From left to right: Mr. Pascal Dacher (Health Manager), Ms. Emilie Montfort, Ms. Virginie Boulanger, Mr. Cyril Dadier (Radiographers), GIE IRM Medical Imaging Center Beauvais (Centre d'Imagerie Médicale du Beauvaisis), France.

The MR Theater Offers a Greater Sense of Escape and Improves Imaging Quality

Revolution, evasion, comfort: These words would best describe the MR Theater, Canon Medical's groundbreaking technology to ease MRI examinations, according to Pascal Dacher, Health Manager at the GIE IRM Medical Imaging Center Beauvais (Centre d'Imagerie Médicale du Beauvaisis), France, where the equipment has recently been installed.

The Medical Imaging Center in Beauvais, northern France, treats all MR requests for all types of clinical applications except cardiology. "We perform osteopathy, neurology, oncology, women's imaging, and pediatrics examinations," Mr. Dacher said.

A main challenge in clinical practice is to secure imaging diagnosis, particularly in anxious, claustrophobic and pediatric patients, who are traditionally more difficult to scan.

To tackle this issue, the team has recently installed two Canon Medical Vantage Orian large aperture MR systems, one of which is equipped with the MR Theater.

A new MR experience

It has been shown that performing examinations in relaxed, cooperative patients improves image quality and diagnosis. Feeling at ease helps patients lie still during the examination.

Control room of the Vantage Orian at GIE IRM Medical Imaging Center Beauvais (Centre d'Imagerie Médicale du Beauvaisis), France.

The MR Theater, which projects peaceful, virtual and immersive reality inside the bore, helps distract patients from the ongoing examination and reduce the stressful and claustrophobic effects of MR.

This is the reason that motivated Mr. Dacher and his team to purchase Canon Medical's technology. "Our ambition is to support all our patients as best as possible during imaging examinations, by offering them a new MR experience. We want to take care of a maximum of claustrophobic patients and children. We believe that the MR Theater can be a relaxation and distraction device that will facilitate management of these patients," he said.

The GIE IRM Medical Imaging Center is used to taking bold steps to improve patient experience. The team notably installed France's first Titan system in March 2009 and was one of the first imaging centers to offer to any patient the performance of comfortable MR examinations inside a wide-opening tunnel (71 cm).

"We have always paid attention to our patients' comfort. We aspire at setting ourselves apart from other imaging centers, by offering innovative and exclusive comfort technologies. Our best ambassadors are our patients. We are convinced that the MR Theater will help us further improve our patients' comfort," he said.

"We were stunned by the immediate impact on our patients, their enthusiasm and spontaneous acceptance. The immersive film helps to distract them."

Mr. Pascal Dacher, Health Manager at the GIE IRM Medical Imaging Center Beauvais (Centre d'Imagerie Médicale du Beauvaisis), France.

Canon Medical's Vantage Orian with MR Theater at GIE IRM Medical Imaging Center Beauvais (Centre d'Imagerie Médicale du Beauvaisis), France.

High acceptance and better results

The team performs any kind of clinical examination with the MR Theater for every patient, but gives priority to claustrophobic and pediatric patients.

Patient reception of the new MR Theater has been overwhelmingly positive, with patients feeling pleased, free and less lonely. Although Mr. Dacher and his colleagues knew the technology would make a difference, they didn't expect such an instant response.

"We were stunned by the immediate impact on our patients, their enthusiasm and spontaneous acceptance. Our patients confirm they have had a more pleasant time and a greater sense of escape. They feel less lonely in the examination room. The film that is being projected in an immersive and realistic way helps distract them," he said.

Oncology patients undergo numerous MR scans as part of their treatment follow-up and have been particularly sensitive to this technology.

Caregivers have also welcomed the effect of reducing stress and claustrophobia on imaging quality. With the help of the MR Theater, clinicians can complete MR exams quickly and capture the high-quality images they need for accurate diagnosis and treatment.

"Patients are more relaxed, more receptive and more cooperative, which greatly facilitates the performance and quality of examinations. The MR Theater helps achieve patient cooperation and immobility, and thus secures image quality and avoids having to repeat sequences. The patient spends less time in the MR tunnel; the examination is generally faster and better," Mr. Dacher concluded. //

Left: Mr. Pascal Dacher, Health Manager at the GIE IRM Medical Imaging Center Beauvais (Centre d'Imagerie Médicale du Beauvaisis), France. Right: Patrice Coudray, Product Manager MR, Canon Medical Systems France.

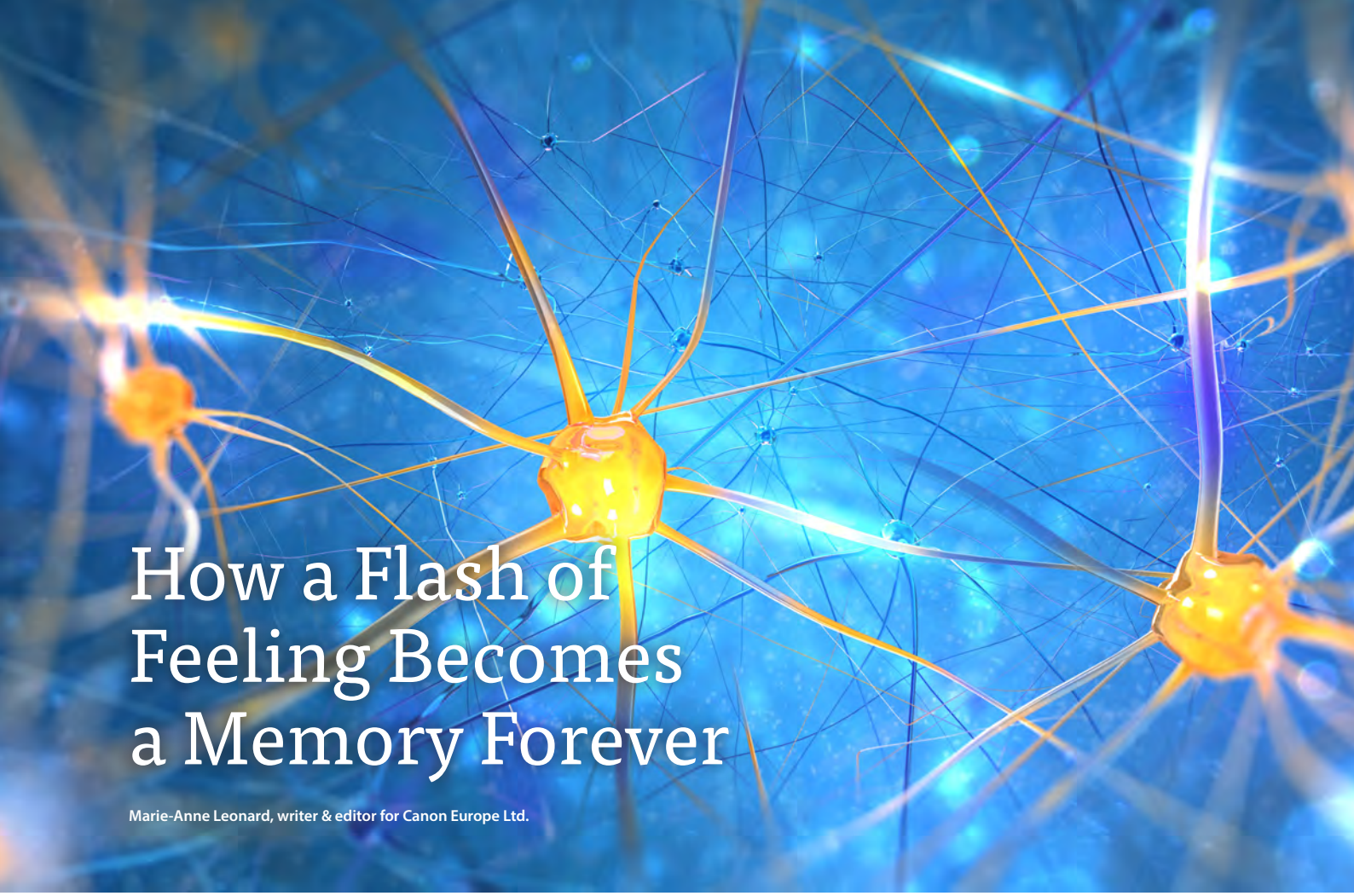

How a Flash of Feeling Becomes a Memory Forever

Marie-Anne Leonard, writer & editor for Canon Europe Ltd.

In Roman times 'genius' took the form of a god or spirit which travelled with humans throughout their lives and channelled great acts through their 'owners'. No human was a genius, but they had the services of a genius. Imagine that today – perhaps reading this on a supercomputer the size of your palm in the knowledge that someone's personal divine entity put it there. Sound ludicrous doesn't it?

In today's world we own our own smarts. The things we create, the places we find and the stories we tell to share them are the result of less philosophy and theology (although they influence our day-to-day lives), and more creativity, economics and science. As we discover new things, we want to share them. Often, we do this as a way to monetise them. And our incredible brains – not those of a borrowed genius – hold the keys to do it all.

To this end, our genius for storytelling has always been with us – from cave drawings to the great oral tradition and the first written words to the Gutenberg press. Throughout the ages, stories have played an important part of life. They function as great moral tales or warnings for children, they share historical events through generations and commemorate the loved. Every family has their own and every day we accumulate more. Today there are more stories in the world than people. More to share. More knowledge. More world. How do we stop our own stories from getting lost?

"The human brain can process an entire image in as little as 13 milliseconds"

There's no map or instructions for getting an idea inside people's heads and keeping it there, but we now know enough about psychology and neuroscience to understand what happens in the human brain when it forms attachments to stories. Creating the initial hook that turns the human 'attentional spotlight' to your story is one thing – but what does the human brain need to turn that quick flash of attention into a meaningful attachment? And it truly is a quick flash: the human brain can process an entire image in as little as 13 milliseconds. Are you selling something?

Reporting news? Raising awareness for a cause? Asking for donations? Whatever you're using your story to do, then this is the sequence responsible for turning feelings into actions:

The hook

A sense of tension that can hold the attention for more than a couple of seconds can effectively connect the brain to the subject for long enough to kickstart the process of arousal – the brain is readying a response and that could be physical (increased heart rate, sweaty palms, a sense of alertness) or emotional. And off our brains go, taking what we've seen and transforming it into something we feel through a complex flurry of neural activity.

The reward

Of all the neurotransmitters (chemicals that pass messages through the nervous system), Dopamine is the fun one and makes us feel good. It's the way our brain rewards us and is released when we eat, take exercise or engage in a pleasurable activity. And because of this it also helps us hold our attention, engage our memories and process the information in front of us. When we see something exciting, appealing or intriguing, dopamine tells us so – and makes us want more of it.

"Why do we remember some stories and not others? What happens in our brains when our attention is piqued?"

The bond

Have you ever seen someone yawn and then yawned too? That'll be mirror neurons. Humans learn by mimicking and these neurons play a big part in our development – including the learning of deeper emotional functions, like empathy. When we build high emotion into our storytelling, it can create an almost contagious effect as these mirror neurons kick in to teach us how to respond to it.

The sense of belonging

A neuropeptide, Oxytocin is best known as the 'cuddle hormone' because of its role in childbirth and maternal binding, but it's far from being a female-only neurochemical. Its release signifies a willingness to trust and readiness to belong, which sounds largely abstract in the context of storytelling, but its presence is a vital step towards your ultimate goal – 'transportation': the process of mentally 'losing yourself' in the story.

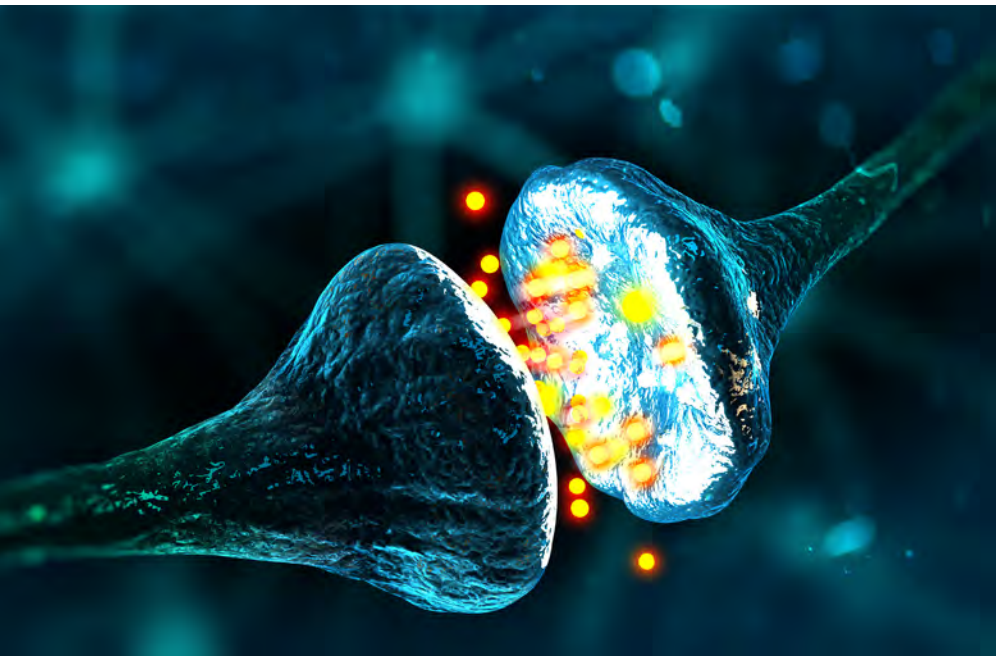

However, it's important to remember that different people will respond differently depending on their own experiences, so if you're telling a story for commercial purposes, then it's absolutely necessary to know who you want to appeal to in order to create a narrative that resonates with them. But it seems that some elements are consistently more successful than others. Massachusetts Institute of Technology conducted a study on memorable images and found that that the most successful photos, in terms of recall, contain people, followed by static indoor scenes and then human-scale objects. Landscapes, although pleasing to the eye, were largely forgettable.

It may be a huge over-simplification, but the stories that stick with us should – at least chemically – be the ones that intrigue and reward in the short-term, but also provide a deep sense of empathy, involvement and belonging as they play out. Whether it's spoken word, a film, commercial, novel or single image, successful stories share a chemical balance that makes them last. //

Artificial Intelligence to Boost MR Imaging Quality and Productivity

The power of AI is brought to routine MR imaging by Canon Medical's Deep Learning Reconstruction (DLR) technology: Advanced intelligent Clear-IQ Engine (AiCE). AiCE is the world's first fully integrated DLR technology for MRI.

One of the main challenges in MRI is finding the optimal balance between the signal-to-noise ratio (SNR) and image resolution. A higher spatial resolution could improve visualization of structures, but when spatial resolution is increased, SNR drops. To regain SNR, typically scan times need to be increased, reducing patient comfort and decreasing throughput.

"AiCE changes the way we think about MRI."

Prof. Garry E. Gold.

Canon Medical found a solution in artificial intelligence: AiCE. AiCE is a deep-learning based solution trained on vast amounts of low and high signal-to-noise MR images to detect noise and remove it from the MR images. By removing noise, AiCE enables spatial resolution to be increased or acquisition time to be reduced.

AiCE expands diagnostic capabilities, enriches radiologist's confidence and reduces examination times and thus improves patient comfort. With AiCE we enter a new era in MRI. //

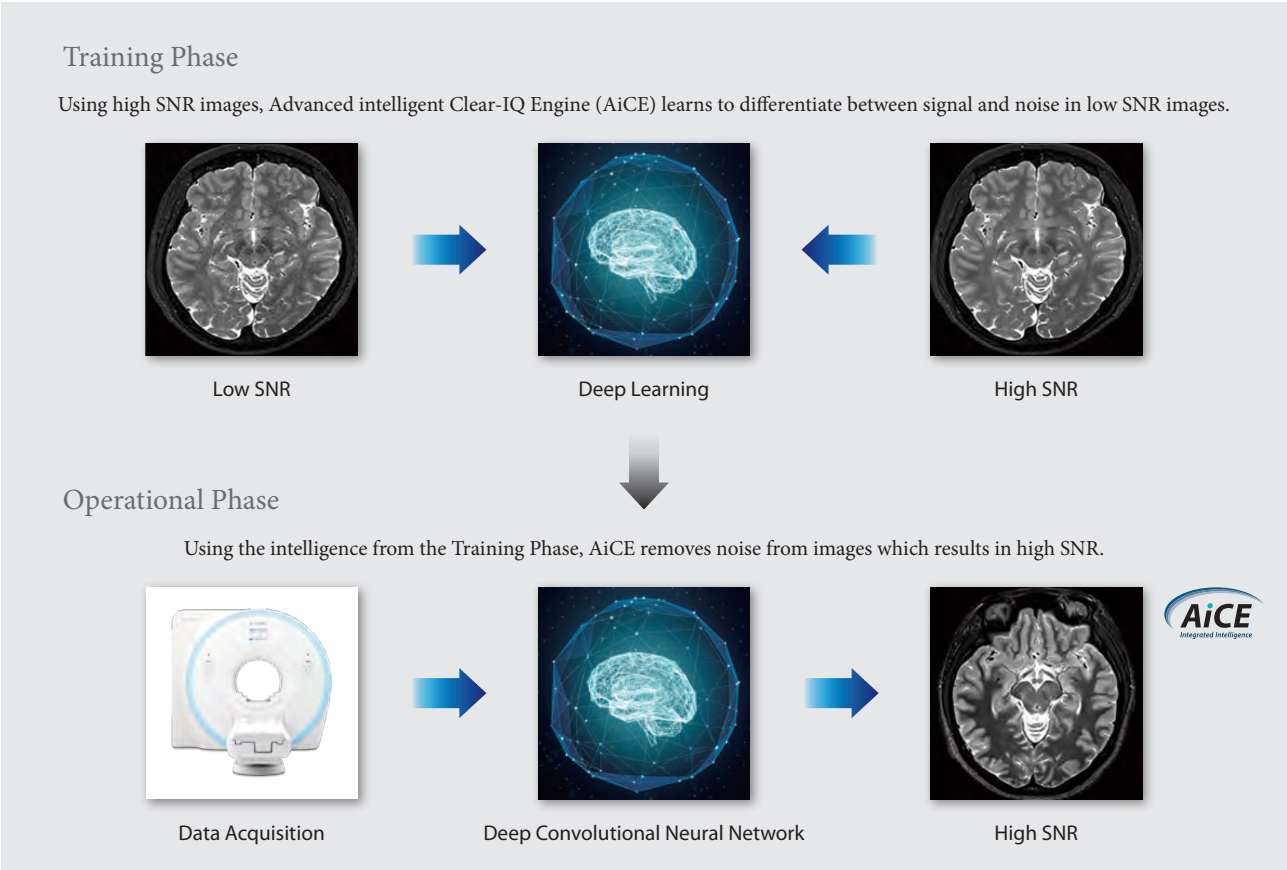

"With DLR we can achieve both high resolution images without losing time or signal and reduce the image acquisition time."

Prof. Vincent Dousset,
Head of the diagnostic and therapeutic Neuro Radiology department at Bordeaux University Hospital.

"I'm impressed by the ease-of-use, how it maintains image contrast and structural detail, while at the same time eliminating noise."

Prof. Garry E. Gold,
Clinical radiologist and researcher, Past president of the International Society for Magnetic Resonance in Medicine (ISMRM) and the Society of Computed Body Tomography and Magnetic Resonance (SCBT/MR)

PD STIR - 1024 x 1024 matrix - 3mm slice thickness

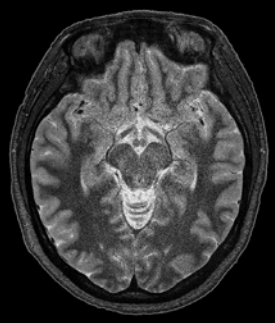

Standard Image
1 Average - 1:45 min

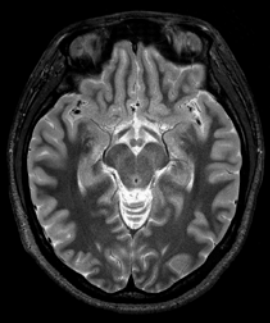

Improved quality by long scan times
10 Averages - 16:49 min

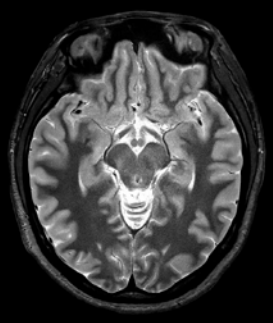

Improved quality by AiCE
1 Average - 1:45 min

Fast knee protocol with AiCE on Vantage Orian 1.5T

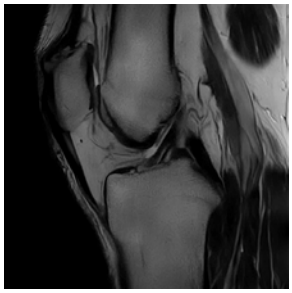

Sag T2 - 0.5 x 0.5 min - 0:56 min

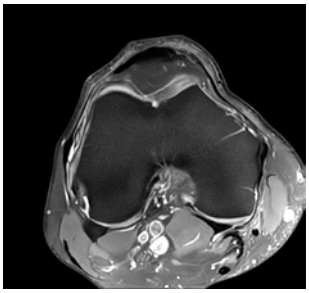

Ax PD FatSat - 0.6 x 0.6 mm - 1:30 min

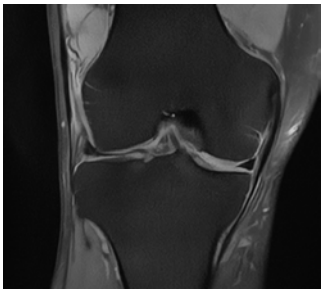

Cor PD FatSat - 0.6 x 0.6 mm - 1:15 min

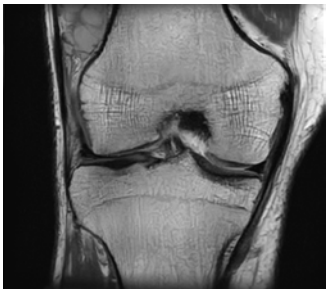

Cor PD - 0.5 x 0.5 mm - 0:58 min

What is Synthetic MRI?
Olea Nova+ is the future

Thiele Kobus

Synthetic MR images are generated through calculation from acquired images and this MRI technology is gaining increasing interest. While the technique was already described in the 1980s, the high computational powers of current PCs make it possible to generate Synthetic MR images in real-time, extending its potential for clinical applications tremendously. Canon Medical together with Olea Medical offer a complete package for Synthetic MRI: Olea Nova+. VISIONS explains the technical background behind this.

Relaxation: The basis for MR contrast

To make an MR image, differences in magnetic properties between tissues are leveraged. Two important magnetic properties are the longitudinal (T1) relaxation time and transverse (T2) relaxation time.

Transverse relaxation time

T2-relaxation time is related to transverse magnetization. When no excitation pulse is applied, there is no transverse magnetization. By applying an excitation pulse, transverse magnetization is created. This transverse magnetization decays again over time. The speed at which the transverse magnetization decays defines the T2-relaxation time (Figure 1).

Longitudinal relaxation time

Although there is no transverse magnetization without excitation pulses, there always is longitudinal magnetization. The longitudinal magnetization is in 'thermal equilibrium'. By applying a 90-degree excitation pulse, the longitudinal magnetization is temporarily lost. After the pulse, the longitudinal magnetization will regrow to thermal equilibrium at a speed known as T1-relaxation time (Figure 1).

Tissue differences = contrast

Following a certain time after the excitation pulse, a difference in longitudinal and transverse magnetization occurs for tissues with short- and long T1 and T2 relaxation times. This tissue property is utilized to obtain contrast in MR images (Table 1).

Imaging parameters

As well as differences in the relaxation times, imaging parameters contribute to MR contrast. Echo time (TE) and repetition time (TR) have the biggest influence. With these parameters, the time between the excitation pulse and the

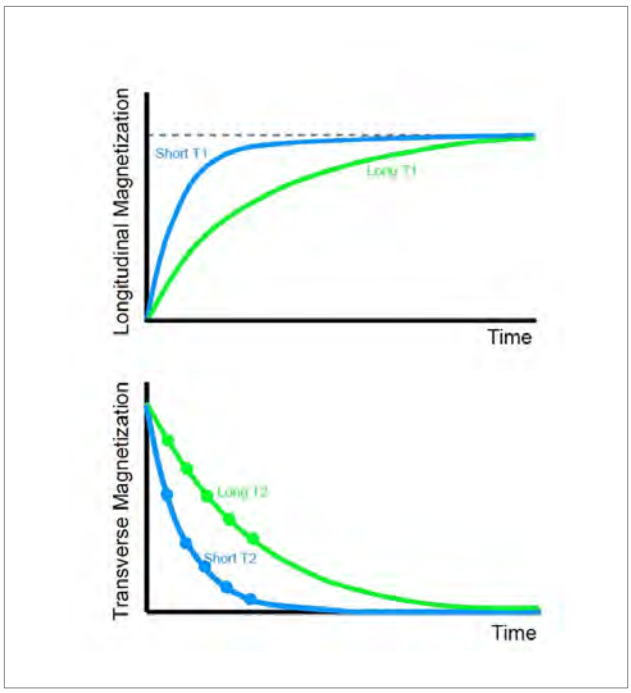

Figure 1, A fast return or magnetization drop means a short T1 or T2 relaxation time (blue lines) and the slow return or slow magnetization decay has a long T1 or T2 relaxation time (green lines).

Tissue	T1 (ms)	T2 (ms)
Water/CSF	4000	2000
Grey matter	900	90
Muscle	900	50
Fat	250	70

Table 1, Approximate relaxation times for different tissues at a field strength of 1.5T.

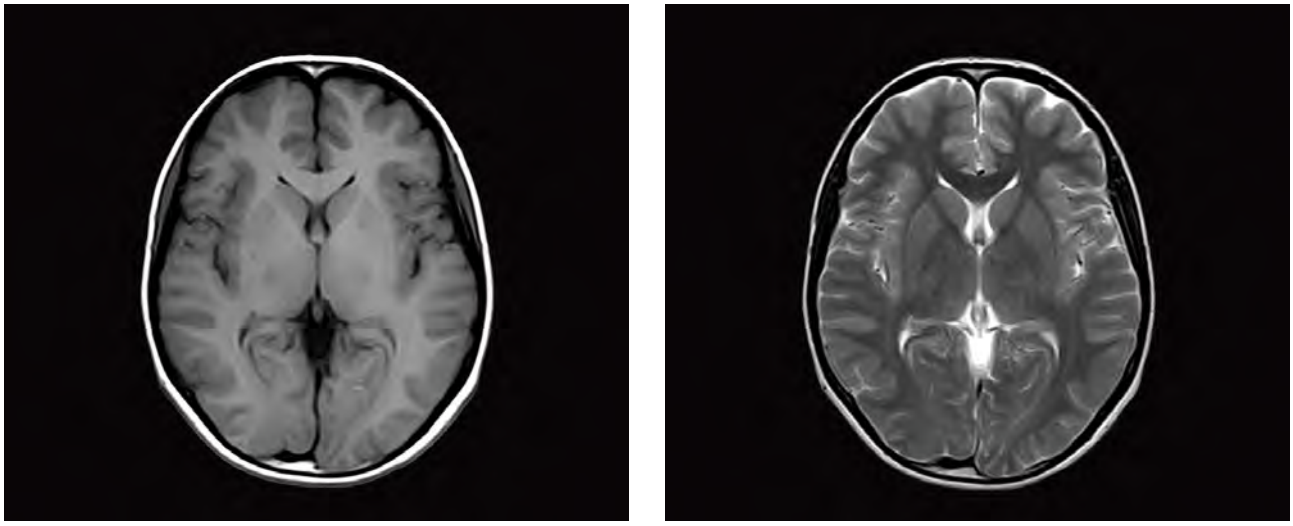

Figure 2, Axial MRIs of the brain. Left: T1-weighted image (short TE and TR). Right: T2-weighted image (long TE and TR).

sampling (TE) or time till the next excitation pulse (TR) is set. The operator can select these imaging parameters to give optimal contrast between two or more tissues.

Figure 2 shows differences in T1 and T2 relaxation times. For a T1-weighted image, we choose a short TE and TR, while for the T2-weighted images, both TE and TR are long. Many combinations in TE and TR are possible; however, to acquire many different contrasts, MR examinations can become very lengthy. Furthermore, different pathologies can alter the relaxation times of the tissue, which could lead to a sub-optimal image contrast for diagnosis. To overcome this, it would be desirable if the imaging parameters could be altered retrospectively. This is possible if you know the actual T1 and T2 relaxation times. Based on these values, you can calculate how the tissues would behave under different imaging conditions. The method to create new images from these calculations is called Synthetic MRI.

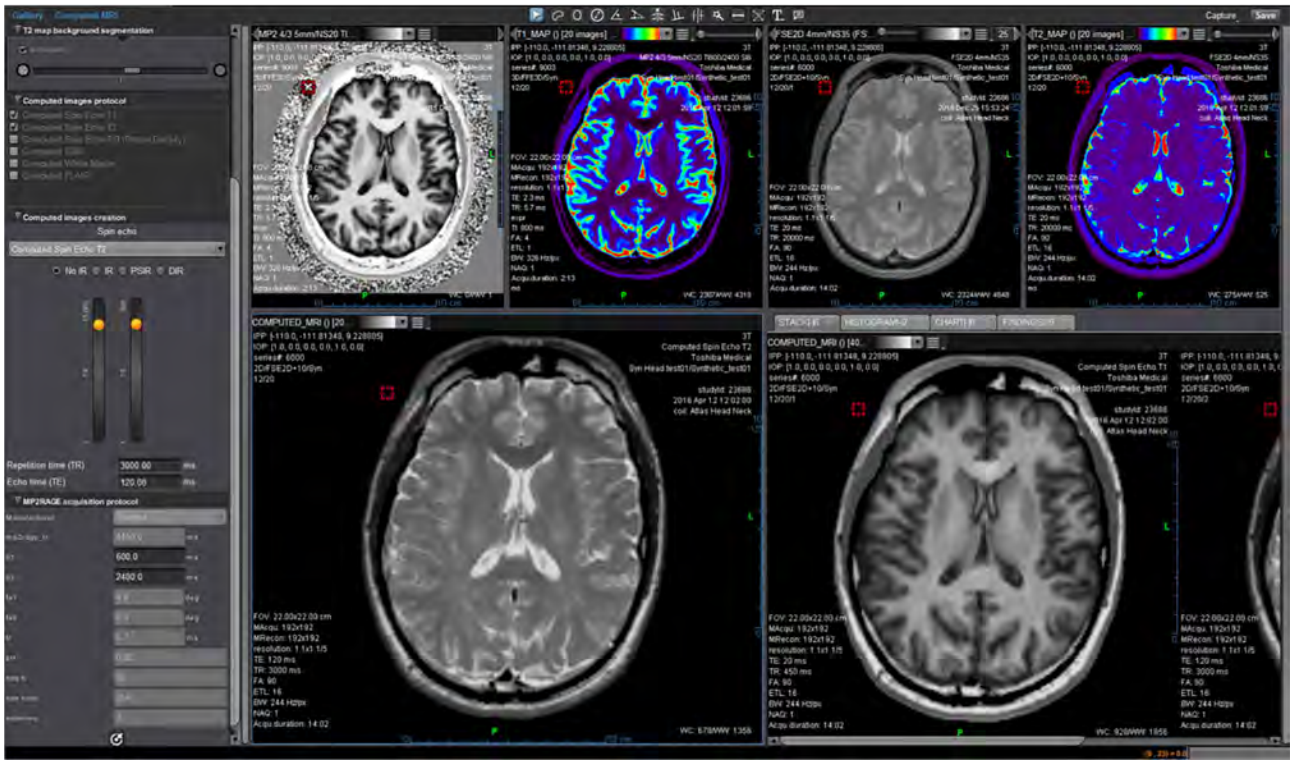

Figure 3, Olea Nova + software. Top row: MP2RAGE images from which the T1-map is calculated and FSE mEcho images used to calculate the T2-map. Bottom row: Two synthetic images with different imaging parameters.

How we do it?

Canon Medical MR systems require two sequences to be able to calculate T1 and T2 relaxation times. To measure the T2-relaxation time, we use a 2D FSE mEcho (2D Fast Spin Echo Multi-Echo) sequence. This sequence acquires the signal multiple times after an excitation pulse (illustrated by dots in the T2-relaxation graph in Figure 1). The longer the time between the excitation and the signal acquisition (TE), the smaller the transverse magnetization becomes. This is an exponential process and the Olea software fits the data points to obtain the T2-relaxation time (Figure 3 – top right).

For the computation of the T1 relaxation time, we use a MP2RAGE sequence (Magnetization Prepared 2 RApid Gradient Echo). This sequence starts with inverting the longitudinal magnetization of all tissues and samples the regrowth of the magnetization at two different time points after this inversion. In the Olea software, the signal intensity at these two time points is fitted and the T1 relaxation time is determined at each voxel (Figure 3 – top middle). Before the fitting process of both the T1 and T2 relaxation times, motion correction is applied.

Now that the T1 and T2 relaxation time is known at every position in the image, the software can synthesize new contrasts using signal equations that describe the signal intensity based on the T1, T2, TE, TR and TIs (inversion times). To create a T1-weighted image, a short TE and TR can be selected. The software then calculates the contrast obtained with these settings, presenting the result immediately. This new synthetic image can be saved and exported. To change the contrast again, the parameters can be altered (Figure 4) and a new image is created, without the patient needing to be present.

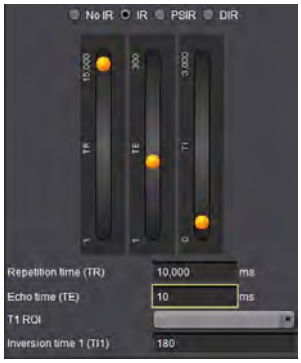

Figure 4, Selection of the imaging parameters.

Advantages and challenges

Synthetic MRI could alter the way MR images are acquired and interpreted. In a typical MR examination, several different contrasts are acquired. Many could be replaced by Synthetic MR images. This could significantly decrease scan time. Much greater flexibility is possible. The radiologist can alter the contrast after the MR examination and make additional contrast images without time penalties. The radiologist can access quantitative images of T1 and T2 relaxation times. This information could be very beneficial for follow-up examinations, as tissue changes can be compared quantitatively. Alongside this, contrasts that are difficult to obtain in vivo can be calculated , (e.g. examinations with long TEs or double inversion recovery (DIR) sequences). When acquired on the scanner, these sequences may have low signal-to-noise ratios, due to decayed magnetization.

A bonus is that the effect of metal artifacts is reduced in synthetic images cf. acquired images, which can improve image interpretation in e.g. MSK exams of patients with implants.

Despite these advantages, routine clinical use of Synthetic MRI will take some time. Radiologists are used to reading weighted images displayed in black-and-white, so it takes time to get a feeling for the quantitative (colored) maps of relaxation time (Figure 3). Furthermore, the contrast of a synthetic image with a certain TE and TR may look different to acquired images with the same settings.

A potential issue are the small partial volume artifacts that can occur at the edge of structures. However, these are easy to recognize by radiologists aware of their existence. Due to the endless contrast options available, radiologists might see structures that they are not as familiar with, requiring a return to their books! //

Thiele Kobus
European Product Manager MRI Canon Medical Systems Europe.

Towards a Quantitative Era in MRI

Prof. Luca Saba

Professor Luca Saba, Head of the Radiology Department of the University Hospital of Cagliari, Sardinia, Italy, is an established and award-winning international radiology research professional. Enthusiastic about the advantages of Synthetic MRI, he shares his views on this new technique and his experience with Canon Medical's new Olea Nova+ with VISIONS.

Why are you particularly interested in Synthetic MRI?

"There are two levels of interest in Synthetic MRI; research and clinical. I think that the technique could have a significant impact in both."

"Firstly, for research, it is a cutting-edge technology with many advantages. It is easy to define a new hypothesis by using this technique in research, as everything remains to be proven. This is an important point. It's like writing a new book - Right now, we only know the letters, but we are starting to use them to write words, sentences, chapters, and so on.

Secondly, on a more technical basis, is that we can explore the intrinsic properties of the tissues. We can obtain pieces of information that do not depend upon the sequences or the magnetic fields but are intrinsic properties.

In the past, it was not possible to assign a unique number to a specific tissue. This was one of the limiting factors in MRI. When we conduct a study and demonstrate something based on signal intensity, we currently do not use a number, but say that it is brighter, or darker, compared to the muscle, for example.

These are obvious limitations compared to CT, in which we can assess that water is zero and fat is below -80 Hounsfield units. Previously, MRI, has been lacking a quantitative approach. Now, we are moving towards phenotypic and quantitative values - This is a concept of biomarkers. Synthetic MRI is allowing us to move towards a quantitative era of MRI.

With this, thirdly, we can move towards standardization of MRI interpretation. If we can assert that a tissue under examination has a value of 800 signal intensity, and we know that 800 is the normal value of the grey matter, we can conclude that there is no epilepsy for example, because the grey matter in that region is normal. This means that standardization in interpretation could be applied and a new database in terms of T1 and T2 values of tissues could be created. It is a new language!"

"As mentioned, there is also a clinical impact. With synthetic MRI , we could theoretically reduce acquisition time. As other sequences can be created from only two originals, we can show that the acquisition time could decrease by acquiring both original sequences and comparing the generation time.

Also, the aim of our next studies is to determine if conventional and Synthetic MRI series qualities are similar; if they are, then we can demonstrate that images obtained with Synthetic MRI could, therefore, potentially replace conventional sequences.

In addition, with Synthetic MRI post-processing, it is possible to obtain missing sequences. This is not possible with a conventional approach. After performing a study with the general protocol, we can read the examination 24 hours later, for example.

If, at that time, we realize that one sequence is missing, we can still obtain it if Synthetic MRI sequences have been acquired. This is a strong point from a clinical point of view, and we have already performed this in reality. In one case, a specific sequence was missing, because of a particular approach, but, with Synthetic MRI, we were able to reconstruct it afterwards. It is really useful!

Finally, Synthetic MRI allows standardization of workflow. In the future, if this approach is confirmed as robust, we could only have Synthetic MRI, diffusion and something

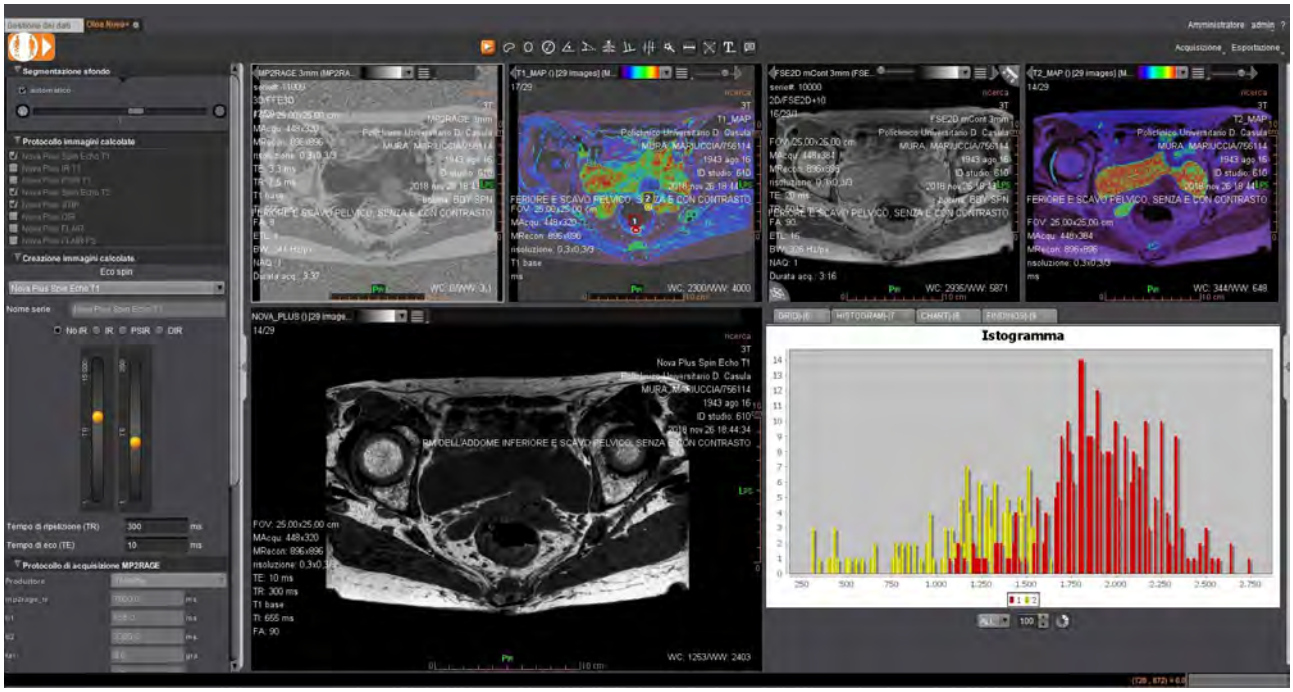

Figure 5, Olea Nova+ application in rectum. First row: MP2RAGE with T1 map and 2D FSE mEcho with T2 map. Second row: synthetic T1w image, histogram shows T1 values of neoplasm (red) and healthy tissue (yellow).

else, which gives us a very simple approach, but provides all the information we need. Moreover, this could avoid errors in the acquisition protocol. Most institutes have a high personnel turnover, however, working with MRI requires time to improve skills and understand techniques. With a simplified approach, we can avoid mistakes."

What is your experience so far with Olea Nova+?

"We are currently using Olea Nova+ in different organs: brain, rectum, prostate and musculoskeletal (MSK) imaging. For prostate, what is interesting is that we have patients who have undergone biopsy or prostatectomy, so their Gleason score is available.

The protocol is very simple; so, when we have time to perform it, we do so in a general clinical setting. For brain, there are cases with some types of pathologies where we always use Synthetic MRI. Therefore, we have a data bank with control subjects and some groups of patients with pathologies.

That is very important, because if we want to create a database of T1 and T2 values in normal brain – this has not been done yet, we need normal brains.

Ongoing studies concern validation among readers and acquisitions on the reproducibility of the sequences obtained from Synthetic MRI, compared to the conventional sequences in clinical practice of brain MRI. We have made presentations to the European Congress of Radiology (ECR) 2019, in which we demonstrated the flow charts and the advantage with regard to time, since it theoretically removes about six to seven minutes.

That is important, because compared to the 22 minutes conventional protocol, we could move to 15 minutes for a high throughput center."

The sequences required for Olea Nova+ provide quantitative information about T1 and T2 relaxation times. Does it bring new relevant information compared to qualitative MRI images?

"Of course, we have also studied the contribution of the quantitative analysis. For example, in rectal and prostate cancers, we analyzed the differences in T1 and T2 values between healthy tissues and tumors and found a significant difference in the distribution of these quantitative values between normal and pathological areas (Figure 5).

This is the future, and it is simple.

What could also be interesting is to combine Olea Nova+ with Olea Texture analysis. The massive approach implies that we use all the available features. If we have 120 features, we should use 120 and test to identify which feature has the best performance. So, we could say at the end: the best thing is to perform MRI with the two sequences required for Synthetic MRI, add the quantitative analysis and use the convolutional matrix inverse feature, for example. There are so many opportunities."

Prof. Saba graduated in Medicine from the University of Cagliari in 2002. His research interests focus on Multi-Detector-Row Computed Tomography, Magnetic Resonance, Ultrasound, Neuroradiology and Diagnostics in Vascular Sciences.

His work is embodied in more than 250 papers published in high impact scientific journals, including Lancet Neurology, Radiology, the American Journal of Neuroradiology, Atherosclerosis and European Radiology. Prof. Saba's work has been recognized by 18 scientific- and extracurricular awards during his career. He has presented more than 500 lectures, papers and posters in National- and International Congresses (RSNA, ESGAR, ECR, ISR, AOCR, AINR, JRS, SIRM, AINR); has written 21 book-chapters; is the Editor of 10 books; and reviews more than 60 scientific journals.

Prof. Saba is member of the Italian Society of Radiology (SIRM), European Society of Radiology (ESR), Radiological Society of North America (RSNA), American Roentgen Ray Society (ARRS), and the European Society of Neuroradiology (ESNR).

Synthetic MRI was the first project jointly led by Canon Medical and Olea Medical® teams. What do you think about collaborative imaging?

"I completely share the view that joining forces creates more strength. So, if we can create a connection, a cooperation between different experiences, we will create a greater product. I believe that the best thing I have done in the past was to create connections with my colleagues by identifying the people who could collaborate with different points of view.

This fosters the creation of bigger things. Not alone. Alone, I can do nothing, or not as much. I like this philosophy; it is also mine. I have always thought that it is better to win a game with people than to lose alone." //

Prof. Luca Saba
Head of the Radiology Department at the University Hospital of Cagliari, Sardinia, Italy.

From left to right: Valentin Prevost (Canon Medical Systems Corporation), Bei Zhang (Canon Medical Systems Europe), Prof. Tourdias (Bordeaux University Hospital), Prof. Dousset (Bordeaux University Hospital), Bruno Triaire and Nobuyasu Ichinose (Canon Medical Systems Corporation).

VISIONS spoke with Prof. Dousset and Prof. Tourdias, from the Bordeaux University, France.

Deep Learning Reconstruction in Magnetic Resonance Imaging

Artificial intelligence continues to expand the possibilities brought by medical imaging and advance healthcare. In particular Deep Learning Reconstruction (DLR) used in combination with Magnetic Resonance Imaging has the potential to help diagnose diseases earlier, faster and better. In France, Bordeaux University is working with Canon Medical's DLR solution to fulfill these promises and take the best out of the technology in numerous applications in research and clinical practise.

DLR has the ability to improve image quality by eliminating noise. Removing noise from images with DLR increases signal to noise ratio, helping to obtain ultra high-resolution images. Based on the experience from Bordeaux University, this has provided the opportunity to see anatomy previously not possible on 3T systems.

Applications in research and clinical work

With the help of Canon Medical, the future has already started at the Bio Imaging Institute (French: IBIO[1]), an unique structure that serves as an interface between the clinical work performed at Bordeaux hospital and the research done at Bordeaux University.

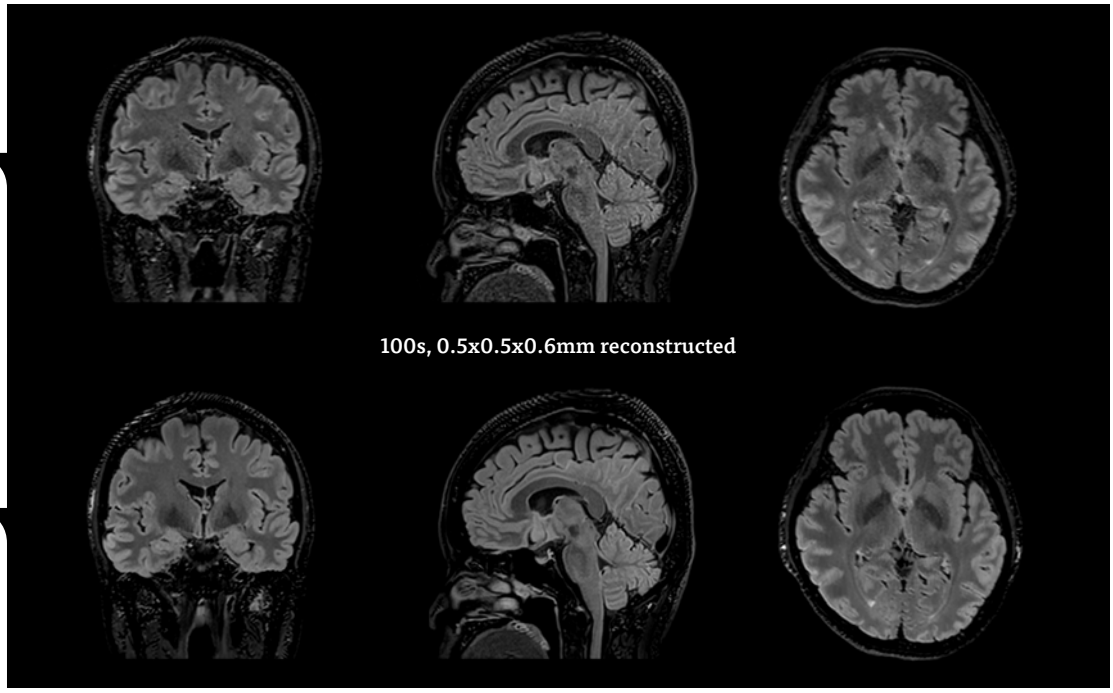

3D FLAIR Original image.

3D FLAIR with DLR.

IBIO started integrating Canon Medical's DLR solution in November 2017. The workload progressively increased during the first six months, to find the optimal parameters and fine-tune the "denoising". The team has been using the system routinely for about a year now and is working on validating the tool scientifically.

Prof. Thomas Tourdias, Radiologist at Bordeaux University, uses DLR in almost all his research projects. "DLR helps to remove noise and obtain better image quality, which assists us to collect more information to answer research questions. Removing noise also helps us to reach a very high resolution that we previously couldn't achieve, which is very helpful for specific research areas," he said.

DLR can be implemented in a myriad of clinical scenarios, for example to help expedite workflow. "In our daily routine, we are challenged with a growing number of requests and the difficult task of examining all these patients. So probably the major clinical application for DLR is going to help us work faster. Many more patients could undergo examinations when we decrease the acquisition time," Prof. Tourdias explained.

DLR is easily integrated into the image reconstruction chain. Radiologists only have to plug in the option to improve the image quality. Switching to this new routine is effortless and brings real benefits, according to Prof. Vincent Dousset, Head of the diagnostic and therapeutic Neuro Radiology department at Bordeaux University Hospital.

"The first advantage is that we can achieve high resolution images with-

"Removing noise also helps us to reach a very high resolution that we previously couldn't achieve."

Prof. Thomas Tourdias, Radiologist at Bordeaux University and Hospital, Practitioner at Bordeaux University Hospital. Also member of INSERM Unit U1215 Pathophysiology of neural plasticity" at the Magendie Neurocentre.

"With DLR we can achieve both high resolution images without losing time or signal and reduce the image acquisition time."

Prof. Vincent Dousset, Head of the diagnostic and therapeutic Neuro Radiology department at Bordeaux University Hospital.

out losing time or signal. The second advantage is the reduction of image acquisition time, as we care less about the signal quality because the noise can be eleminated following the scan," Prof. Dousset said.

DLR is more than just a new tool, it's a major change in medical imaging history, Prof. Dousset believes. "Because the DLR will allow us to correct afterwards what couldn't be corrected at the outset, the first application is that we no longer have to improve the signal or the spatial resolution. This is revolutionary in medical imaging history. This is the main advantage I think: the image "denoising" technique."

In particular DLR has an important clinical impact in anatomical regions that require a very high resolution, for example parts of the hippocampus and the claustrum.

"The DLR brings a spatial resolution that I have never seen before in neurologic imaging. I recently pointed out a brain area, for example the claustrum, that is almost invisible on standard MRI images even with very high resolution or high field devices. However, thanks to the DLR we could highlight this kind of brain anatomy. So, indeed, there is a considerable advantage to using this technique." Prof. Dousset said.

Prof. Tourdias worked at 7T to visualise extremely fine structures of the hippocampus while at Stanford. With DLR, he can now do this task with a 3T. "When we compared the images we realized that by pushing the 3T machine and processing with DLR that we were able to achieve a similar result to what we could achieve with 7T. I think this is the main surprise of the technology." he said.

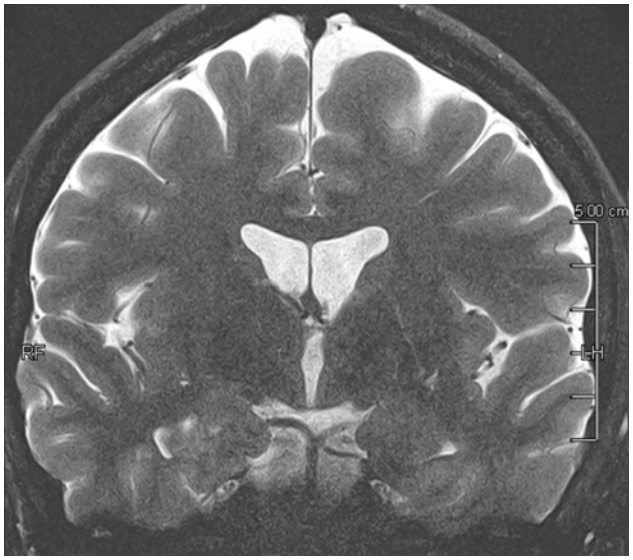

Original Coronal T2w image.

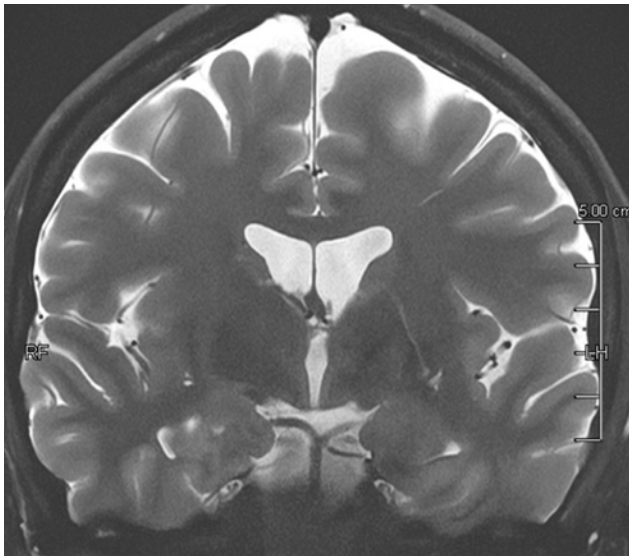

Coronal T2w image with DLR.

Bordeaux University Hospital.

Mutual benefits

The synergy between the hospital and Canon Medical creates opportunities to find solutions for the patient, also in areas that had never been explored before. Working with Canon Medical enables physicians at IBIO to work with the most advanced technology on the company's latest MRI scanner for on-going clinical research, but benefits spread beyond the institute, Prof. Tourdias explained.

"There is an interest in transferring the technology back to the manufacturer, and we hope that the results of this research will quickly spread to the industry. And then it's interesting to put together research projects. So, there are multiple facets to our collaboration," he said.

The strong cooperation between Canon Medical and the medical team at IBIO has also placed the institute among the top, most competitive imaging centres in Europe.

"Canon Medical's collaboration with Bordeaux University helps us position ourselves internationally among the important European academic teams who work with major medical imaging manufacturers. This is a huge benefit," Prof. Dousset said.

Canon Medical's cooperation was essential in installing and becoming familiar with the system and more generally with AI. With Canon Medical's clinical scientists involved all through the process and visiting regularly, the medical team was able to find the optimal settings and make the most of DLR.

"There were a lot of questions about DLR's relevance and benefits, and the different technical parameters that it features. We proceeded to analyse a lot of images, so that we could make choices that had been transcribed by Canon Medical. The manufacturer's contribution was very significant to DLR's development at our site," Prof. Dousset said.

Innovating hand in hand with Canon Medical benefits not only the patient, but also the next generation of radiologists. "It's very important to integrate the industry in education, to prepare students for their future professions," he concluded. //

Reference

[1] *The Bio Imaging Institute (French: IBIO) project was initiated ten years ago to be the interface between Bordeaux Hospital and Bordeaux University. The building hosts research on both animals and humans, with a particular focus on MR imaging, but there are also on-going projects in X-Ray and optical imaging. The IBIO welcomes several academic teams from Bordeaux University and the French National Centre for Scientific Research (French: CNRS), who work on MRI biologic imaging development and neuroscience studies, as well as industrial teams, such as the Canon team for MR work.*

Ultra-High Resolution Head Subtraction CT Angiography in Clinical Practice

Dr. Frederick Meijer, Dr. Ewoud Smit

The Radboud university medical center, in Nijmegen, the Netherlands, installed an Ultra High Resolution Aquilion Precision CT scanner from Canon Medical last year. The Radiology team have already completed research in subtraction techniques in angiography using this system. The principle researchers include Dr. Frederick Meijer, Radiologist, Head of Neuro Radiology, and Dr. Ewoud Smit, Radiologist.

"The Ultra High Resolution Aquilion Precision™ CT scanner (UHR CT) has been used in clinical practice at our hospital since October 2017. It is integrated into our routine workflow for the whole range of CT applications, including diagnostic imaging of the head and neck," explained Dr. Meijer. "Non-contrast head CT scans on Aquilion Precision are scanned in normal resolution mode (with collimation 0.5 mm, matrix size 512mm x 512mm), with diagnostic image quality equivalent to the other CT scanners in our department - the Aquilion ONE™ ViSION Edition and Aquilion ONE™ GENESIS Edition CT systems from Canon Medical. In UHR mode, the collimation for the Aquilion Precision is 0.25mm and the scan is reconstructed with a matrix of 1024mm x 1024mm to reduce pixel size."

Dr. Ewoud Smit, Radiologist, and Dr. Frederick Meijer, Radiologist, Head of Neuro Radiology.

Canon Medical's Aquilion Precision at the Radboudumc, Nijmegen, the Netherlands.

Routine subtraction scanning

"We are impressed that the radiation dose of CTA in UHR mode has proved to be comparable to CTA on conventional CT scanners, attributed to optimized detector elements and a data acquisition system redesigned for UHR CT," said Dr. Meijer. "At our department, UHR subtraction CTA is now routinely applied in the follow-up of patients with a cerebral aneurysm that has already been treated."

Detecting and analyzing complex aneurysms

A cerebral aneurysm can be detected if the patient has an intracranial subarachnoid hemorrhage, due to aneurismal rupture. A cerebral aneurysm may also be found as an incidental finding on CTA or MR Angiography (MRA). In both situations, it should be considered to treat the aneurysm to prevent aneurismal rupture or re-bleed. Cerebral aneurysms are treated either by surgical clip placement, endovascular stent or flow-diverter placement; or with coil-embolization, depending upon the location, size and configuration of the aneurysm.

Radboudumc, Nijmegen, the Netherlands.

Patients with a cerebral aneurysm that has already been treated require follow-up to evaluate the level of aneurysm occlusion, or possible recanalization. If the aneurysm is not fully occluded, or if it is recanalized, the patient remains at risk of aneurysm rupture that can result in intracranial hemorrhage. In this case, additional treatment should be considered.

Replacing DSA with subtraction CTA

"Patients with a cerebral aneurysm are treated with a surgical clip, endovascular stent, or flow-diverter and undergo follow-up imaging with subtraction CTA," said Dr. Meijer. "Otherwise, the patients would require follow-up with conventional digital subtraction angiography (DSA) - an invasive and costly procedure that carries the risk of transient or permanent complications. DSA is only performed when the image quality of subtraction CTA is suboptimal, or if there is doubt about the aneurysm occlusion."

MRA is not feasible in these patients due to susceptibility artifacts from the surgical clips and stents. In the follow-up of endovascular coil-embolization treated aneurysms, MRA is the preferred imaging modality. However, some patients cannot undergo an MRI examination due to unsafe implants (e.g. a pacemaker), or because of claustrophobia. In these cases, subtraction CTA can be considered as a good alternative to DSA.

"Together with neurosurgeons from our hospital, we have performed a prospective cohort study to evaluate the diagnostic accuracy of subtraction CTA using a conventional CT system (Aquilion ONE ViSION Edition) as compared to DSA in subjects with a cerebral aneurysm treated with a flow-diverter. A flow-diverter is an endovascular stent-like prosthesis used to treat cerebral aneurysms that are not eligible for coil-embolization.

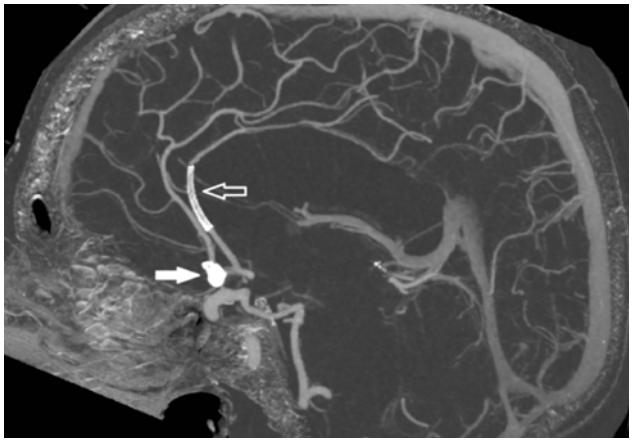

CT angiography scanned in ultra high resolution mode (0.25 mm collimation) demonstrated complete occlusion of an anterior communicating aneurysm treated with endovascular coil occlusion (white arrow) and complete occlusion of a small anterior cerebral artery aneurysm after endovascular flow-diverter placement (open white arrow). Single Energy Metal Artifact Reduction (SEMAR) and a model based iterative image reconstruction algorithm (FIRST) were applied.

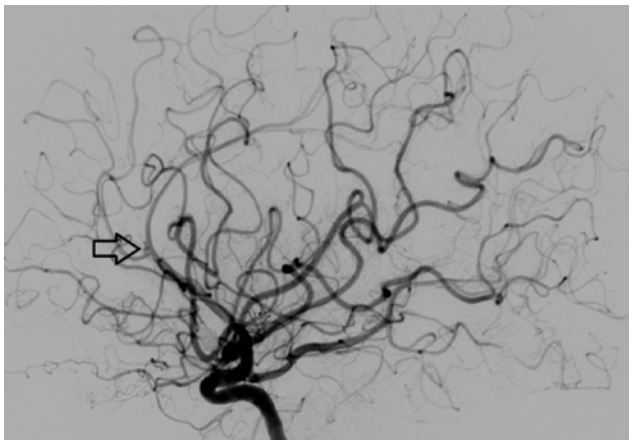

Prior to flow-diverter stent placement, conventional DSA demonstrated a small anterior artery aneurysm.

In subtraction CTA (SURESubtraction), the pre- and post-contrast scans are automatically registered and subtracted. Subtraction CTA with a metal artifact reduction technique (SEMAR) proved effective in reducing flow-diverter metal artifacts, and diagnostic accuracy proved comparable to DSA for the evaluation of cerebral aneurysm occlusion after flow-diverter treatment. For this indication, subtraction CTA has now replaced DSA in our hospital.

A more confident evaluation

On our Aquilion Precision CT scanner SEMAR is also available, and when combined with a dedicated model based iterative image reconstruction algorithm (FIRST, Forward projected model-based Iterative Reconstruction SoluTion) and SURESubtraction, the image quality is superior to subtraction CTA at conventional spatial resolution. The median effective radiation dose estimate of our protocol is around 2.4 mSv (mean DLP 1150, k-factor 0.0021), which is well within the range of standard reference levels and comparable to other conventional CT scanners.

Therefore, we decided that every patient that requires subtraction CTA in the follow-up of a surgical clip or flow-diverter treated aneurysm is scanned in UHR mode on our Aquilion Precision scanner.

"In our initial experience, all cases have been of diagnostic image quality with the majority being rated as good to excellent. As compared to standard resolution subtraction CTA, smaller vascular structures and incomplete aneurysm occlusions are better delineated on UHR subtraction CTA, which is relevant for treatment planning. With the application of a model-based iterative image reconstruction algorithm (FIRST) and SEMAR, only limited artifacts resulting from the implanted materials are encountered, which allows a more confident evaluation of the treated aneurysm. Due to the increased spatial resolution, small and untreated cerebral aneurysms are also better depicted. For treatment planning it is important to accurately evaluate the shape of the aneurysm, to identify branches originating from the aneurysm and to appreciate the aneurysm's relation with surrounding vessels. Of course, our observations need to be verified in prospective cohort studies, which we are currently preparing in cooperation with our neurosurgical department."

"UHR mode scanning in head CTA is currently implemented in our routine clinical practice," said Dr. Smit. "Patients presenting with acute cerebral ischemic stroke are not routinely scanned on the Aquilion Precision scanner, because in this group of patients we perform perfusion CT, where a wide detector is preferred for whole brain coverage. Also, in case dynamic (4D-) CTA is indicated, e.g. for the evaluation of cranial arterio-venous shunts, the patients are primarily scanned on our wide-detector CT scanner. It is expected that increase in spatial resolution, with subsequent improved visualization of small vessels, can be beneficial in these groups of patients as well." //

Dr. Frederick Meijer
Radiologist, Head of Neuro Radiology

Dr. Ewoud Smit
Radiologist

Read the scientific article:

Meijer et al | Ultra-High-Resolution Subtraction CT Angiography in the Follow-Up of Treated Intracranial Aneurysms | Insights into imaging (2019).

Scan the QR code or visit the website.

Dr. Wolfgang Möller (l.)
Neurologist Berlin, Nerve sonography.

Rober Meyer (r.)
Specialist in Neurology Berlin.

Nerve Ultrasound Opens Up Completely New Perspectives

Dr. Möller, why are you offering nerve sonography?
Nerve sonography can be useful, for example, to determine the exact location in case of suspected nerve damage - and to make a faster diagnosis. With the classical examination, the electrophysiological measurement of the nerve conduction velocity, I obtain indications of a changed or disturbed function.

In addition, I may obtain rough indications of where the nerve is damaged, inflamed or pinched. However, I can not clarify the cause of the damage with the electrophysiological measurement. High-resolution ultrasound imaging with one of the most advanced devices, such as the Aplio i800, in the hands of an experienced and well-trained examiner is, in my opinion, the ideal form of investigation to visualize the cause of a nerve disorder.

To what extent has the ultrasound changed your practical work?
Nerve sonography is a relatively new method, which offers far-reaching additional possibilities for neurological diagnostics. Until the 1990s, we had no other method than the electrophysiological measurement. So, above all, we worked with the patient's clinic and the curves of nerve conduction velocity. But we had no idea what a damaged nerve looks like, we did not have a picture. Thanks to high-frequency probes, I can now see and assess even the smallest peripheral nerves noninvasively, three-dimensionally and in real time. That's a great advantage.

What additional information does the three-dimensional image provide?
The three-dimensional insight into the body using the Aplio i800 takes on a whole new dimension, giving us a new perspective on the nerves. You can imagine it like a theater in which a great curtain stands closed before us. Although we can look at the wonderful fabric, its colors and how nice it is - it is only when the curtain opens that the images, actors and scenes that make up the play open up to us.

What does the theater have to do with sonography?
With nerve ultrasound, the curtain opens into the three-dimensional reality of the nerve plexus and its surroundings. On the one hand, I get a look at the individual structures.

"With nerve ultrasound, the curtain opens into the 3D reality of the nerve plexus and its surroundings."

But the ultrasound has changed even more: I can see in real-time a three-dimensional network where one nerve is there, the next one somewhere else. There are also individual variants, each person has a different anatomy.

Through the imaging of, for example, an irritated nerve, one can generally better understand how, for example, irritation develops and which processes take place. So it's not just about the picture we see when we're sitting in front of the device. It's about the entire pathological process, which we understand better through ultrasound. For us, today nerve ultrasound is a significant modern building block in neurological diagnostics.

How do patients react?
From our practical experience, visual nerve sonography, in addition to traditional examination methods such as nerve conduction velocity measurement, is also immensely important for patients. Because they get additional information by looking at the screen, they can better imagine where their pain comes from and how to best treat it. The patient sees his illness and gets a clear idea of it. And the ultrasound offers him or her more security in the treatment due to the clear instructions for the diagnosis.

Can you name typical indications?
The ultrasound can even make small peripheral nerve structures and muscles visible. The investigation can clarify whether a nerve is only pinched as in a nerve constrictor syndrome, whether it is irritated or inflamed. A typical indication is discomfort and tingling in the hands. The ultrasound provides indications as to whether the problem is peripheral or, for example, in the area of the cervical spine. In addition, the nerve ultrasound helps us to weigh up for or against surgery. Preoperatively, however, it can also be revealing, for example, about where to incise - or prepare for anatomical variants.

Nerve sonography fell behind normal ultrasound for a long time.
The technology and development of the sound probes took a long time. But now that the devices are on the market, new improvements are constantly being added. The structures that we can detect with the nerve ultrasound become smaller and more detailed. Nature opens up to us completely differently again. Here with the Aplio i800 Canon offers the best device on the market. We've been working with Canon for years.

Why are you and Canon so close?
We are extremely satisfied with the company in many ways. As Canon offers a service that we rarely find today. For sales, we have such a good contact, I've never experienced that with any other manufacturer. In case of problems, the technicians are immediately accessible, the customer care is excellent. I've experienced that with Canon over the years. The company even provided us with a loaner device very quickly when we had problems with the equipment of another company. We chose the Aplio i800 because it's the first choice in terms of imaging, quality and resolution.

Will the importance of nerve sonography change in the future?
Like me, my colleagues are convinced that nerve sonography will continue to grow in importance in the future. Because most people work on the computer, fine motor, detailed work is becoming increasingly important. We need to be able to help patients quickly and effectively with disorders even of the smallest peripheral nerves. So, diagnostics, for example with the Aplio i800, will make a major contribution in the future. //

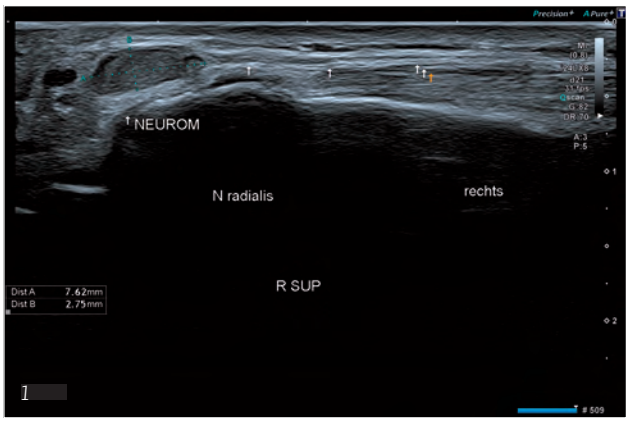

Fig. 1: Here a neuroma after injury in the area of the distal R. superficialis of the N. radialis is shown.

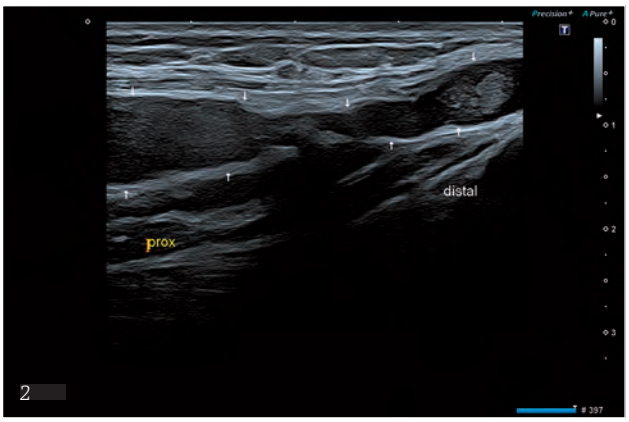

Fig. 2 shows an elongated neuroma / neurinoma in the area of the left ulnar nerve in the upper arm after a long-standing trauma.

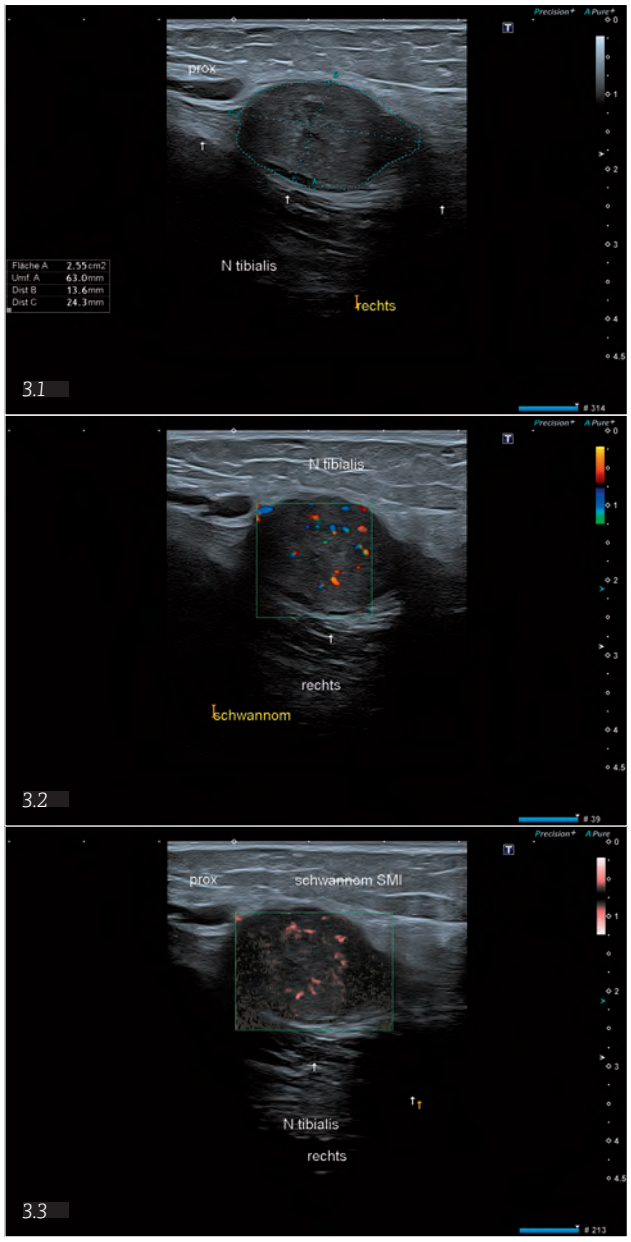

[I] Figs. 3.1 to 3.3 show a schwannoma in the area of the right tibial nerve in the area of the distal lower leg.

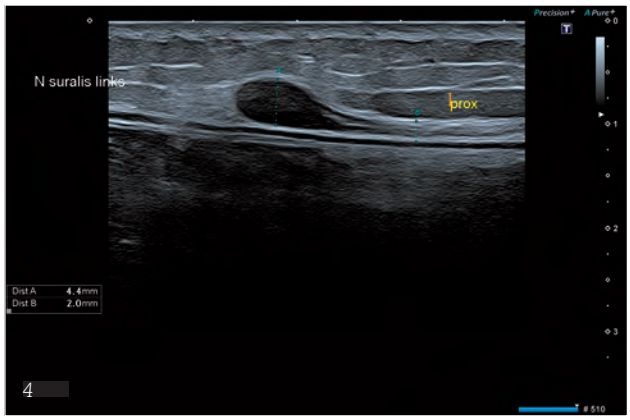

[I] Fig. 4 shows a neuroma formation after injury of the left sural nerve.

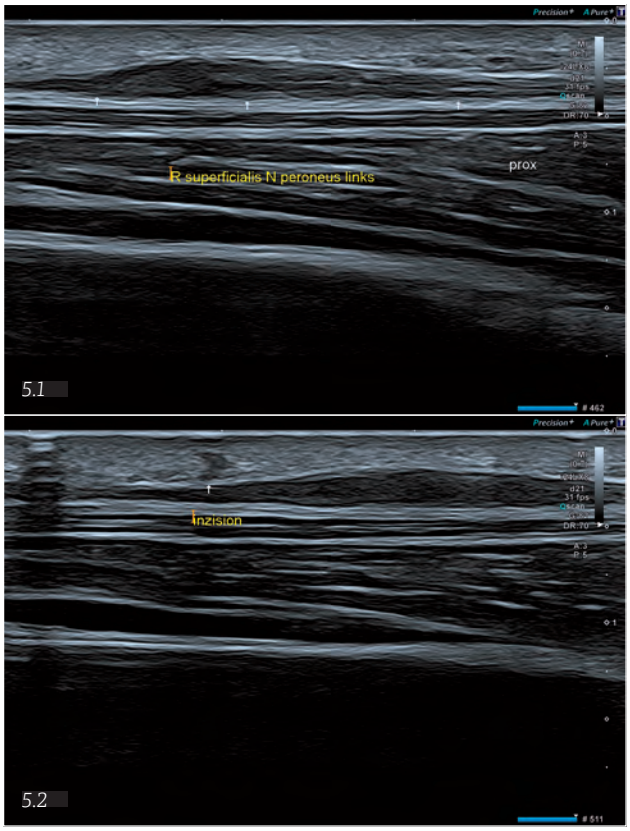

Fig. 5: Incision of the R. superficialis of the N.peroneus.

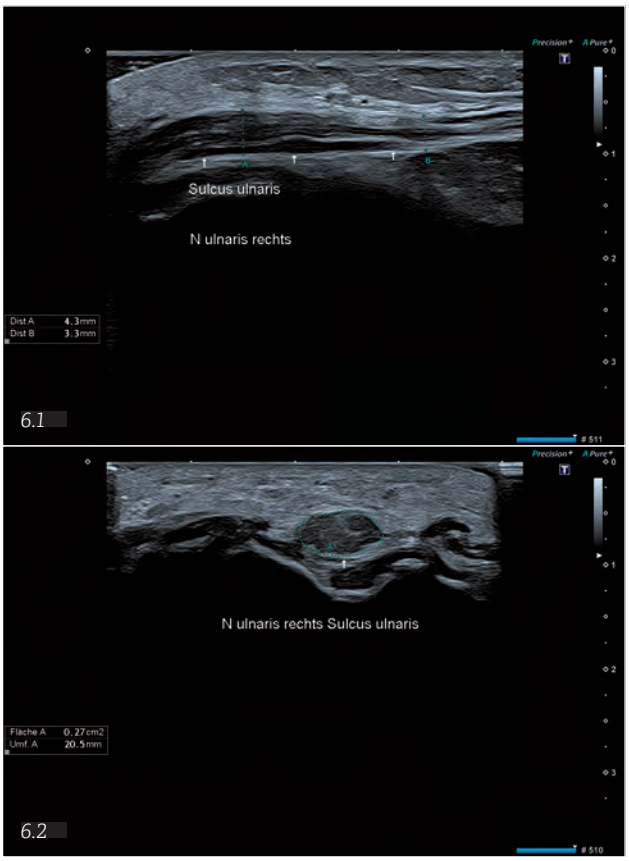

Fig. 6: Ulnariskompression in the area of the sulcus ulnaris right.

More Precise Information with Dual-Energy CT in Neuroradiology

Dr. Sascha Pietruschka

With the 320-row Volume CT Aquilion ONE, the Dietrich-Bonhoeffer-Klinikum in Neubrandenburg in Germany is carrying out Dual-Energy CT examinations, amongst others. In this interview, Dr. Sascha Pietruschka, Senior Consultant in the Clinic for Radiology and Neuroradiology, speaks about the deployment options in Radiology. His conclusion: Less open questions with Dual-Energy CT.

Why and how were Dual-Energy scans first introduced into your clinic?

The focus within the Department of Radiology and Neuroradiology is the diagnosis and treatment of neurological disorders. Within this framework, we also carry out radiological interventional procedures. Two aspects have allowed us to incorporate the procedure here: Firstly, our department has been able to purchase a modern Volume Computed Tomography. The technical requirement was met as a result of this.

Secondly, I have been extremely curious about the uses of Dual-Energy since I heard about the use of Dual-Energy scans in the diagnosis of gout for the first time a few years ago. I have heard many presentations on this topic since then, including on the subject of post-interventional CT. I wanted our patients and doctors to be able to enjoy the benefits of a Dual-Energy CT.

Dr. Sascha Pietruschka with the 320 detector volume-CT Aquilion ONE at the Clinic for Radiology and Neuroradiology.

What clinical questions can you answer with the help of Dual-Energy scans?

Dual-Energy is extremely helpful within the field of Neuroradiology. The procedure can be used to reliably detect or rule out early internal bleeding. Data from Dual-Energy scans is used to generate a "water image", a "calcium image" and an "iodine image".

These raw data images are weighted against one another or subtracted from one another. The findings from the information obtained in these images make it possible to reliably differentiate between bleeding and contrast medium stasis. In our department, this procedure is normally used following revascularization procedures during the first CT follow-up check.

In your opinion, what is the specific added value of Dual-Energy?

In Neuroradiology, we can reliably differentiate between internal bleeding or effects of contrast medium stasis following intervention via Dual-Energy CT. This is information that is crucial to the continuation or introduction of post-interventional anticoagulant therapy. Dual-Energy scans simply offer more information in these patient.

How would you work if you were unable to use Dual-Energy imaging? Would patients have to accept drawbacks?

Without Dual-Energy scans, we would use traditional imaging. However, in the past our diagnisis was not as confident.

Dual-Energy imaging offers a greater level of reliability and confidence in the diagnosis. As we are a full-service provider and we are not a hospital with a research focus, the method

is so far being used for a smaller patient group here at Dietrich-Bonhoeffer-Klinikum. However, the method works very well and brings crucial added value to the routine - we simply have less open questions when we have the Dual-Energy results.

Does the method have disadvantages?
No. The method can lead to a significant head start in stroke treatment compared with routine examinations.

How do Dual-Energy CTs fit into your workflow?
These are routine applications and there is no additional expense. Partners from the respective departments know what they need to note down. They must complete a normal request for a CT examination.

How do you assess the dose in the case of Dual-Energy CTs?
There have been considerable developments in dose reduction with the introduction of interative reconstruction techniques. With the average age of the patients eligible for the examination and the severity of the diseases to be diagnosed, the slightly higher dose is more than compensated by the added diagnostic value.

What future applications do you envisage for your hospital and in general for Dual-Energy scans?
We are considering using Dual-Energy scans after all neurological interventions. I could also easily imagine the Dual-Energy CT being used in tumor imaging. I am also keeping an eye out for other areas of use.

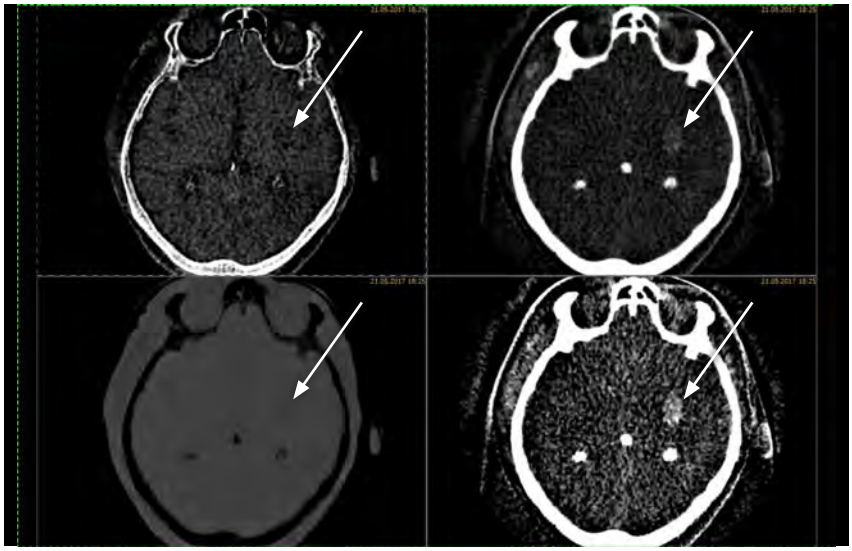

Figure 1.1: Right side images: Iodine basis material (top) and Calcium basis material (bottom images). There is a hyperdense area in the region of the N.Lentiforms. Left side images: the water basis material images show hyperdense areas in the corresponding N.Lentiform region.

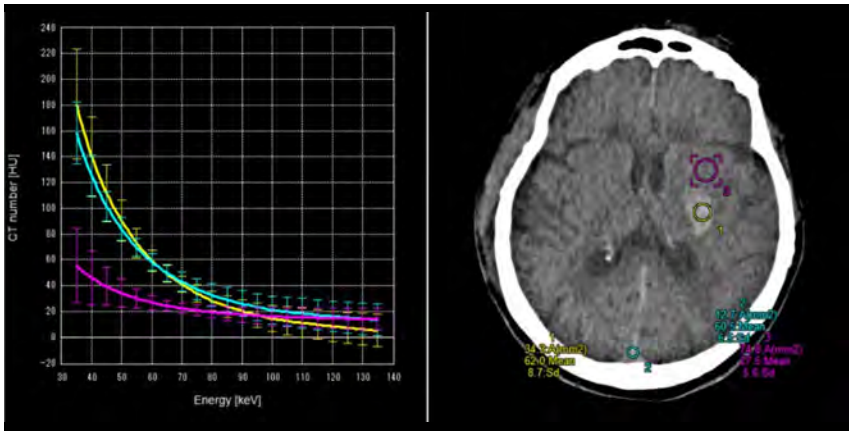

Figure 1.2: The 59 keV monochromatic image shows the hyperdense area in the N.Lentiform region. The spectral curves of this region and the venous sinus show similar upslope typical of iodinated contrast (yellow and blue) as compared to normal brain parenchyma (purple).This confirms the collection is contrast media stasis.

Case 1: Dual-Energy CT following thrombectomy - bleeding or contrast medium stasis?

The 89-year-old patient was found unconscious. There was a monocular hematoma of the right eye and atrial fibrillation. The initial CT showed marked early signs of infarction in the region of the basal ganglia and the insular lobe on the left. An M1 occlusion was diagnosed in the CT angiography.

Due to the unclear time window, an MRI was subsequently performed with the detection of diffusion disturbances in the entire middle cerebral artery area on the left without correlation in the T2 FLAIR image. Together with the Neurologist, the decision was made for an invasive recanalization attempt. Recanalization of the M1 segment was successful.

Subsequent Dual-Energy CT. In this CT contrast medium stasis was found in the N. Lentiform. The Dual-Energy CT made it possible to reliably differentiate between bleeding, which was equally conceivable, and contrast medium stasis.

Case 2: Post-interventional control after coiling by means of Dual-Energy CT: bleeding or contrast agent stasis?

The 59-year-old patient was diagnosed with an 8mm diameter basilar aneurysm. The elective use of the "pCONus Device" was used in an attempt to optimally place one coil, which made it necessary to recover the stent initially inserted with the coil. Subsequently the stent placement and endovascular occlusion with a coil was achieved. No contrast medium appeared to escape throughout the entire procedure.

We decided to carry out an immediate post-interventional follow-up check with Dual-Energy imaging. Here we saw a unilateral cortical band-like to patchy left occipital hyperdensity. Thanks to the Dual-Energy CT, we were able to unequivocally define this change as CM stasis. There was no diagnostic uncertainty. The follow-up CT the next day showed complete resorption of the contrast medium.

Figure 2.1: Angiographic representation before and after care.

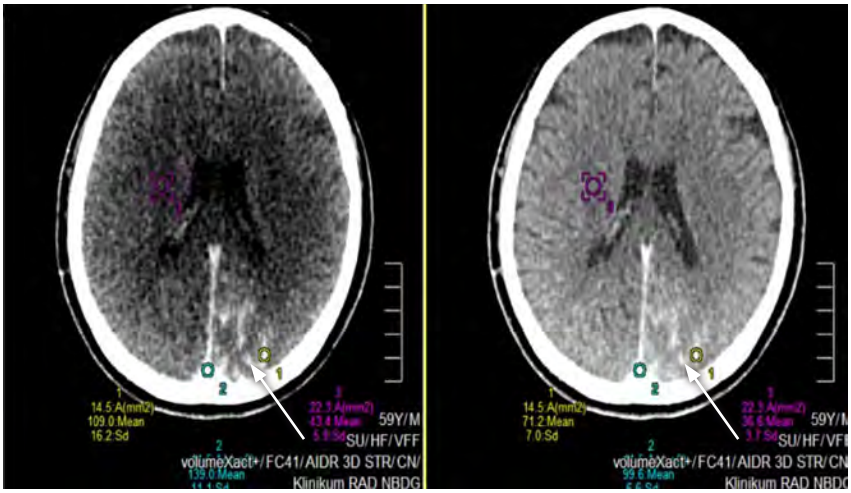

Figure 2.2: 80KV and 135KV image with hyperdense representation of the left occipal cortex band.

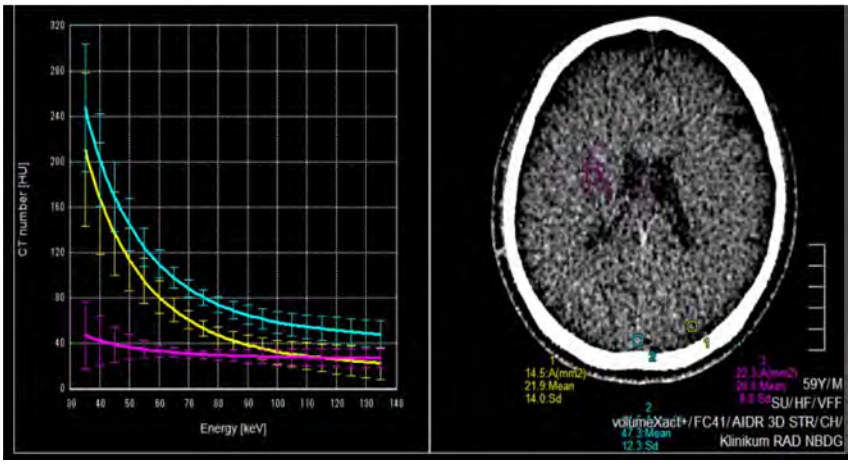

Figure 2.3: the spectral curves demonstrate the typical upslope of iodinated contrast from the ROI in the left occipital cortex (yellow) and sagittal sinus (blue).The normal brain parenchyma curve is shown in purple.

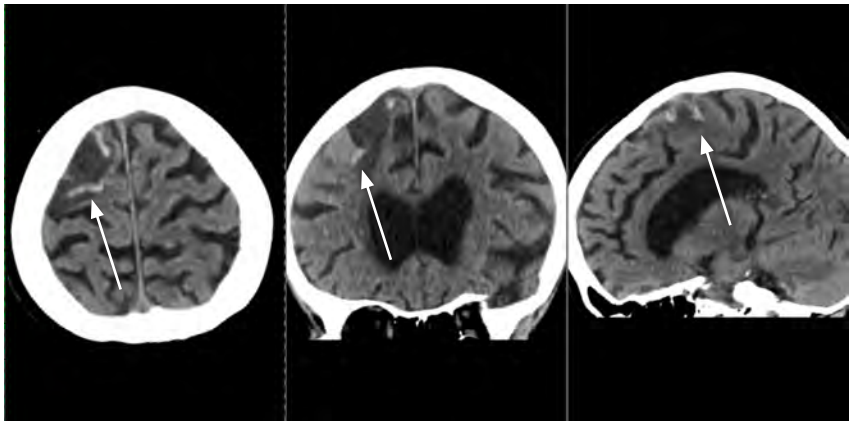

Figure 3.1: Native CCT 120 KV with post ischemic parenchymal lesion on the right in the border area.

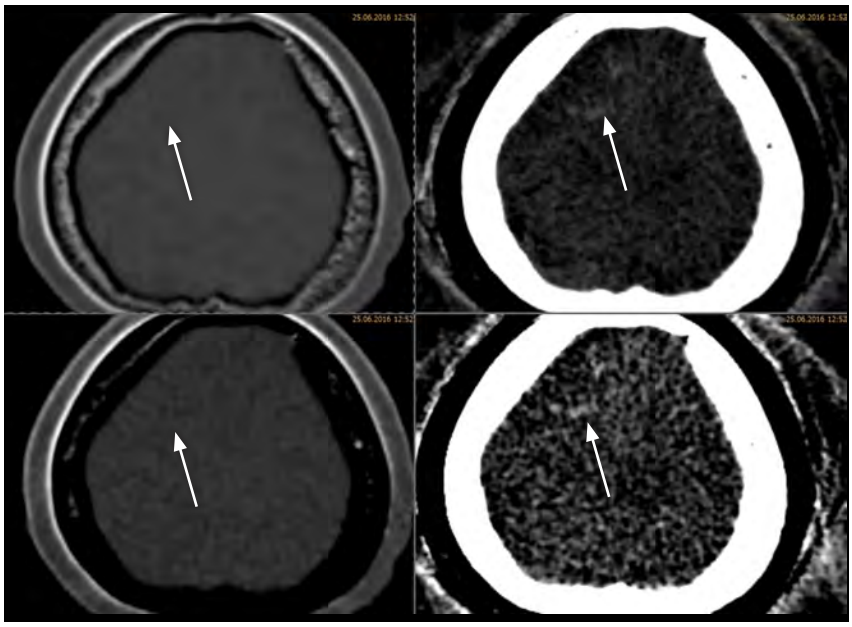

Figure 3.2: Right side images show the iodine basis material (top) and the calcium basis material (bottom) with hyperdensities in the edge area of the old infarct. The water images (left hand side) show these area as iso-dense suggesting calcifications.

Case 3:
Raw data subtraction image to distinguish between bleeding or a calculus

At the beginning of May 2017, the patient suffered a watershed infarct as a result of carotid dissection on the right. After stabilizing the patient on a new oral anticoagulant, rehabilitation measures ensued. Two seizure events accompanied by falls occurred eight weeks after the first incident. These led to inpatient admission. In the CT on admission, we saw band-like, but not continuous hyperdensities in the peripheral region.
Thanks to a Dual-Energy scan using specific parameters bleeding was rapidly ruled out by means of an assessment of the raw data subtraction images. There was a calcification in the peripheral region of the infarcted tissue. //

Dr. Sascha Pietruschka
Consultant at the the Radiology and Neuroradiology Department, Dietrich-Bonhoeffer-Klinikum in Neubrandenburg (Germany).

Canon

Automation Platform

The right insights. Accelerated by AI.

Automation Platform is an AI-based, zero-click solution that uses deep learning technology to streamline your workflow for fast, actionable results every time. From scanner to clinical decision, you'll be supported by leading-edge deep learning technologies that process and deliver images for accurate triage, worklist prioritization and treatment decisions.

For more information, contact your local sales representative or visit our website:
https://eu.medical.canon/products/healthcare_it/automation-platform

AUTOStroke solution

As part of our Automation Platform offering, we've created an innovative solution that helps optimize treatment outcomes for stroke patients when speed and accuracy are everything.

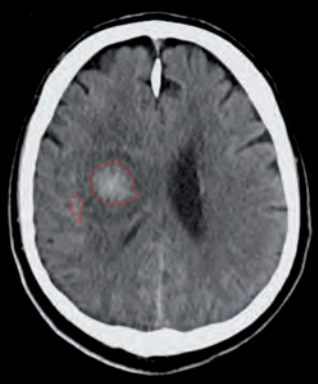

Non-contrast CT Intracranial Hemorrhage

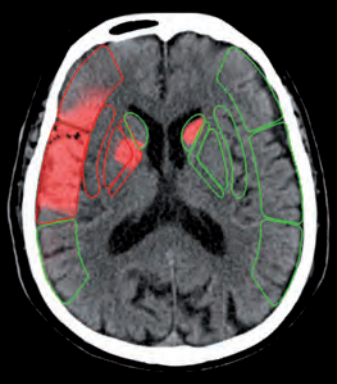

ASPECTS

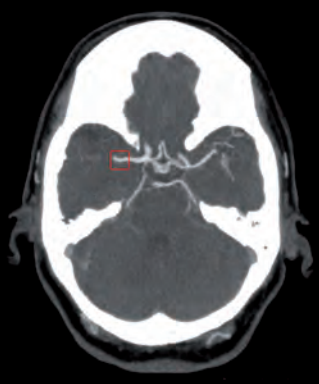

CT Large Vessel Occlusion

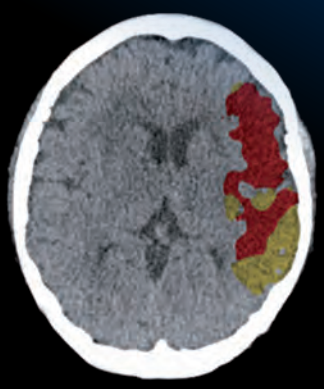

CT Brain Perfusion maps

CANON MEDICAL SYSTEMS
https://eu.medical.canon

Made For life